

American Pediatric Surgical Association

---

# Standardized Toolbox of Education for Pediatric Surgery

## Necrotizing Enterocolitis

APSA Committee of Education  
2012-13



# Necrotizing Enterocolitis

---

**Wolfgang Stehr, MD**

**Children's Hospital and  
Research Center Oakland, CA**

# History

- **Brief HPI**

- 6 day old premature infant 900gram birthweight
- born at 28 weeks of gestation
- abdominal distension, vomiting
- apneas, bradycardias and desaturations
- had been fed premie formula for past 3 days

# History Discussion Slide

## What other points of the history do you want to know?

- **Characterization of Symptoms:**
  - Abdominal distention firm/tender
  - Appreciate dilated loops of intestine/mass
  - Abdominal wall edema
  - Abdominal wall cellulitis/erythema
- **Temporal sequence**
  - Rapid deterioration of general status
  - feeding well for past days, then increased abdominal distension
- **Associated signs/symptoms:**
  - Feeding intolerance
  - High residuals
  - Bilious output 75%
- **Pertinent PMH**
  - Cardiac anomaly? (PDA)
- **ROS**
  - What type of feeds? What rate?
- **MEDS**
  - Is patient on cardiac or respiratory support?
- **Relevant Family Hx**
  - Drug use?

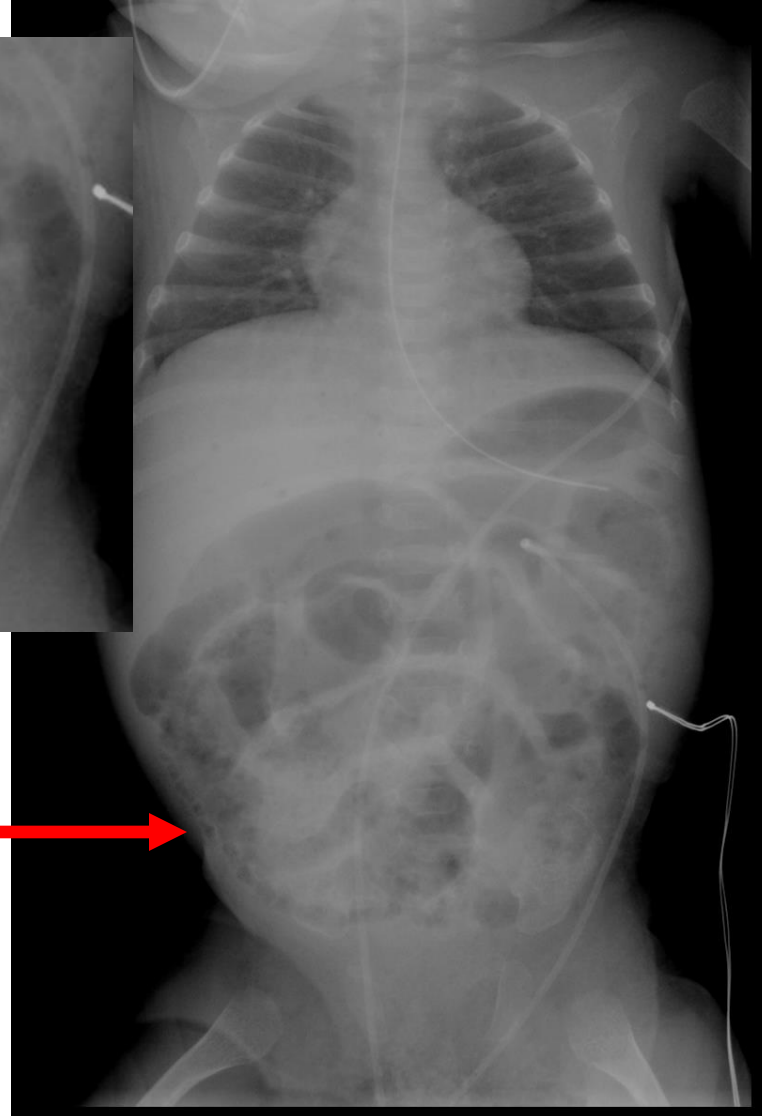
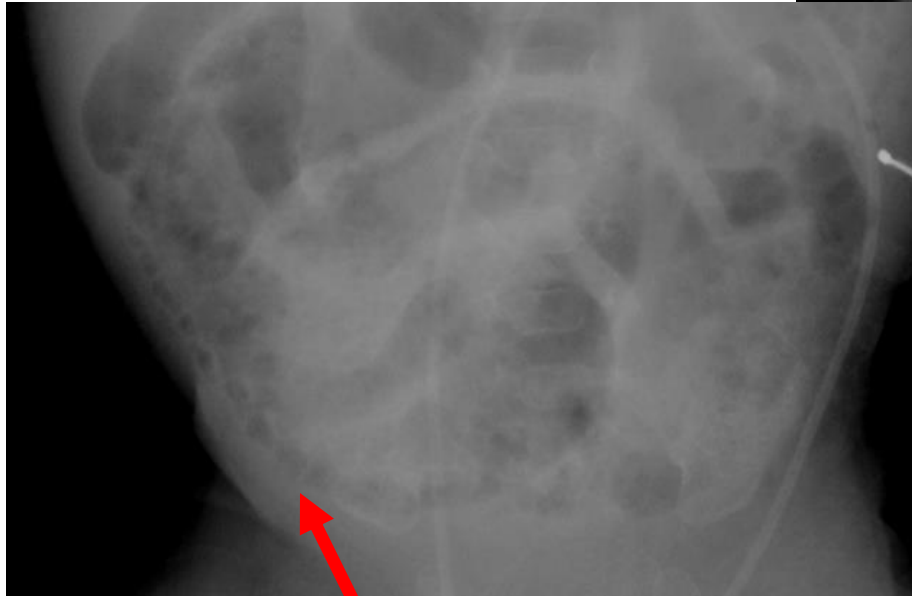
# Physical Exam

- **What specifically would you look for?**
  - **Vital Signs:**
    - Fever not helpful (artificially created in incubator)
    - Temperature instability
    - Lethargy
    - Apnea
    - Bradycardia
    - Desaturation
  - **Appearance:**
    - Sick appearing, edematous abdominal wall
    - requiring increasing support

# Studies (Labs, Imaging)

- **Laboratory abnormalities**
  - High or low WBC with left shift
  - Thrombocytopenia
  - Metabolic acidosis (70-90%)
- **What Imaging Needed**
  - Supine abdominal Xray (babygram) with right side up lateral decubitus cross-table image

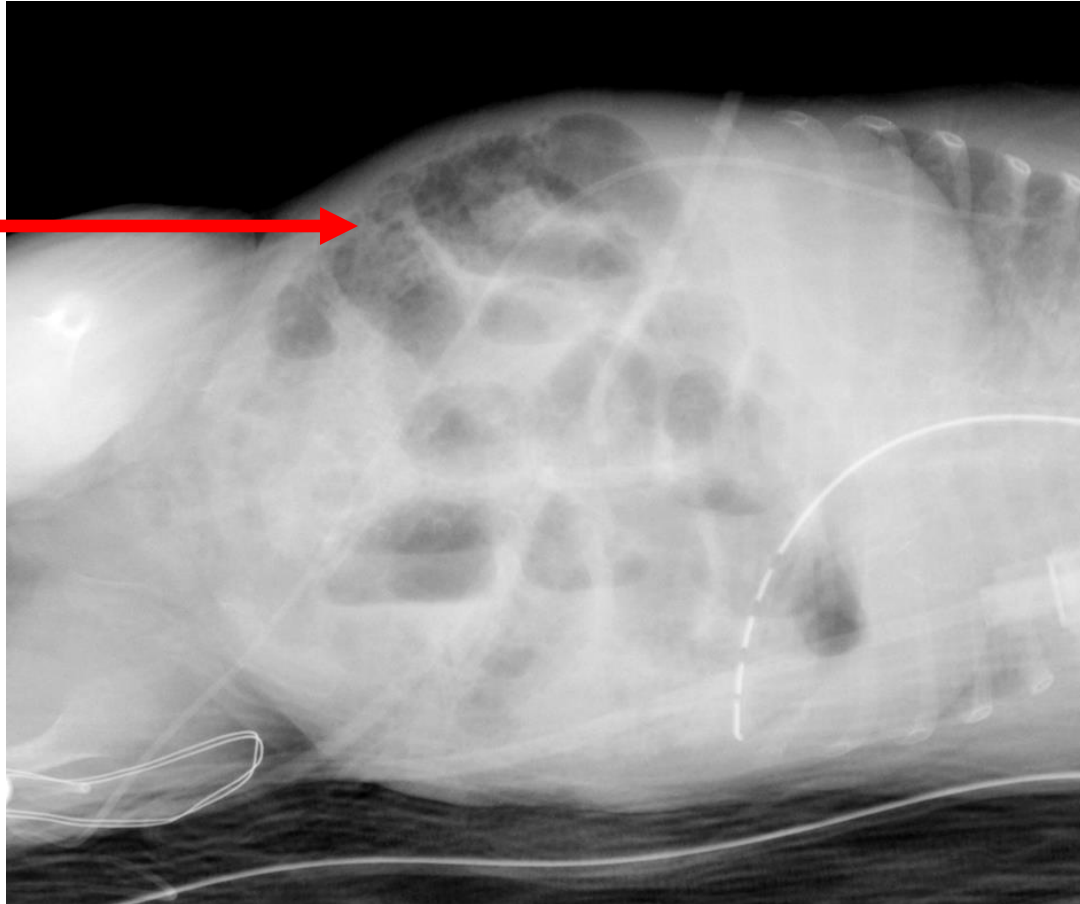
# Study Results



Pneumatosis  
intestinalis

# Study Results

Pneumatosis  
intestinalis





# Case Discussion

- **Diagnosis**

- Necrotizing enterocolitis
  - Pneumatosis Intestinalis (pathognomonic, 98% NEC)
- sepsis can look very similar (UTI/Respiratory/Intracranial hemorrhage)

- **Treatment Plans**

- NPO, Antibiotics (e.g. Amp/Gent/Clinda)
- support with iv-fluids
- respiratory support (ventilator)

# Surgery

- **Indications for surgical intervention:**
  - Absolute indication:
    - Free air (pneumoperitoneum)
  - Relative indication
    - Ongoing decompensation (failure of medical management)
    - Persistent thrombocytopenia, leucopenia or acidosis
    - Failure to improve over several days

# Surgery

- **Goal of surgical intervention:**
  - “clean up” contamination (stool/abscess)
  - divert fecal stream
  - remove dead bowel
  - decompress abdominal compartment syndrome

# Operation

- **Operative Options:**
  - **Laparotomy**
    - resection of dead bowel
    - drainage of stool/abscess
    - ileostomy
  - **Placement of peritoneal drain**
    - (infants under 1000 grams)
    - decompression
    - drainage of stool/abscess

# Complications

- **Perioperative**
  - loss of intestinal length
  - bleeding (liver)
- **Postoperative**
  - Intestinal strictures
  - wound-healing problems
  - short-gut syndrome (intestinal failure)

# Post-operative Management

- **Routine milestones for post op care**
  - Continuous support and Antibiotics
  - Nutritional support (parenteral nutrition)
  - Waiting for “healing”/bowel-function
  - reintroduction of feeds
  - Reoperation for intestinal continuity
    - stoma closure
      - 6 weeks after NEC and over 2000g

# Zebra slide

- **Total Parenteral Nutrition (TPN) is required in all infants with NEC**

- 1: during the acute phase

- 2: if short gut and intestinal failure are present

Common side effect of prolonged TPN is TPN induced liver disease (cholestatic liver failure)

End stage liver and intestinal failure may require liver and intestinal transplantation.

# Questions

- **3 weeks after nonoperative treatment of an episode of NEC a 1200gr baby has persistent abdominal distension, high NG output and is not passing stool.**

**Why?**

- A: inguinal hernia
- B: unrecognized abscess
- C: Hirschsprungs disease
- D: intestinal stricture
- E: intestinal obstruction



# Questions

- **3 weeks after nonoperative treatment of an episode of NEC a 1200gr baby has persistent abdominal distension, high NG output and is not passing stool.**

**Why?**

- A: inguinal hernia
- B: unrecognized abscess
- C: Hirschsprungs disease
- D: intestinal stricture
- E: intestinal obstruction

**Answers: D and E most likely, A and B possible**

# Questions

- **1100gram infant has newly diagnosed pneumatosis intestinalis, and gas in the liver parenchyma. No signs of pneumoperitoneum. What is the treatment?**
  - A: Emergent liver and small bowel transplant
  - B: Antibiotics for NEC
  - C: Laparotomy to remove the affected intestine
  - D: Placement of penrose drain at bedside
  - E: Changes in ventilator settings

# Questions

- **1100gram infant has newly diagnosed pneumatosis intestinalis, and gas in the liver parenchyma. No signs of pneumoperitoneum. What is the treatment?**
  - A: Emergent liver and small bowel transplant
  - **B: Antibiotics for NEC**
  - C: Laparotomy to remove the affected intestine
  - D: Placement of penrose drain at bedside
  - E: Changes in ventilator settings

# Questions

- **After 2 days of antibiotic treatment, 15 day old former 26 week GA infant (700gr) with NEC has decreased abdominal distension and now pneumoperitoneum on today's x-ray.**
- **What is the treatment?**
  - A: change antibiotic regimen to include antifungal therapy
  - B: laparotomy, resection of perforation and ileostomy
  - C: placement of abdominal drain at the bedside
  - D: continue current care as abdominal distension is improving
  - E: Repeat x-ray to follow the pneumoperitoneum

# Questions

- After 2 days of antibiotic treatment, 15 day old former 26 week GA infant (700gr) with NEC has decreased abdominal distension and now pneumoperitoneum on today's x-ray.
- **What is the treatment?**
  - A: change antibiotic regimen to include antifungal therapy
  - **B: laparotomy, resection of perforation and ileostomy**
  - **C: placement of abdominal drain at the bedside**
  - D: continue current care as abdominal distension is improving
  - E: Repeat x-ray to follow the pneumoperitoneum

» Answer: B; C

# Final Discussion/Review

- **Top 5 take home points for NEC**
  - 1: Risk factors: Prematurity and very low birth weight
  - 2: Breastmilk decreases risk vs formula feeds
  - 3: Pneumoperitoneum is indication for surgery
  - 4: Antibiotic treatment, bowel rest and supportive care
  - 5: Short gut and parenteral nutrition associated liver disease are common sequelae

# Acknowledgement Slide

---

**The preceding educational materials were  
made available through the  
American Pediatric Surgical Association**

**In order to improve our educational materials  
we welcome your comments/ suggestions:**

[www.eapsa.org](http://www.eapsa.org)