



# Fetal Diagnosis and Therapy

## A Reference Handbook for Pediatric Surgeons **2nd Edition**

from the  
Fetal Diagnosis and Treatment Committee  
of the  
American Pediatric Surgical Association

April 2019

Edited under the leadership of editor Erin Perrone, MD, and the  
2016-2018 APSA Fetal Diagnosis and Treatment Committee

©2019, American Pediatric Surgical Association

## FOREWORD

This handbook is the culmination of the vision and work of those who have served on the Fetal Diagnosis and Treatment Committee of the American Pediatric Surgical Association over the past ten years. The first edition, published in 2013, was the vision of the prior chairs, Francois Luks and Hanmin Lee, and brought to fruition by the original editors Brad Feltis and Chris Muratore. This second edition, under the leadership of editor Erin Perrone and the 2016-2018 APSA Fetal Diagnosis and Treatment Committee, provides updates as the field has continued to evolve to reflect current practice. Additionally, new chapters on the “Fetal Airway” and “Anomalies of the Genitourinary Tract” have been added.

Fetal diagnosis and counseling has evolved from its original niche practice to a field in which most pediatric surgeons are involved, as newborn surgical conditions are increasingly identified in the prenatal period. While very few pediatric surgeons will actually participate in prenatal treatment, most will care for patients with anomalies and malformations detected before birth. This handbook is a ready reference that provides concise information about many common fetal anomalies relevant to the pediatric surgeon. As the field is rapidly evolving, the contents of this handbook have been updated to reflect current knowledge and practice. As newer diagnostic capabilities and treatment modalities evolve, this handbook will surely be updated again by future Fetal Diagnosis and Treatment Committee members. This handbook serves as a quick reference for the pediatric surgeon in preparation for counseling a family with a fetal anomaly and as a useful educational tool for the residents and fellows in training.

Thank you to the committee members who have spent countless hours sharing their knowledge to create this resource, and to you who will use this knowledge to benefit our patients and families.

Terry L. Buchmiller, M.D.  
Chair, APSA Fetal Diagnosis and Treatment Committee, 2016-2018

## CONTRIBUTORS

Fuad Alkhoury, MD	Nicklaus Children Hospital, Miami
William Block, MD, MBA	East Tennessee State University
Brad Feltis, MD, PhD	Children’s Hospitals and Clinics of Minnesota, Minneapolis
Tracy C. Grikscheit, MD	Keck School of Medicine, University of Southern California
Shinjiro Hirose, MD	University of California Davis, Fetal Care & Treatment Center
Nathan P. Heinzerling, MD	Akron Children’s Center, Akron
Corey W. Iqbal, MD	Overland Park Regional Medical Center
Eric B. Jelin, MD	Johns Hopkins University & Children’s Center Fetal Program
Amanda R. Jensen, MD, MS	Indiana University, Indianapolis
Sundeep G. Keswani, MD	Texas Children’s Hospital, Houston
Mitchell R. Ladd, MD, PhD	Johns Hopkins Hospital, Baltimore
Timothy Lee, MD	Texas Children’s Hospital, Houston
Rony Marwan, MD	Children’s Hospital of Colorado, Colorado Fetal Care Center
Christopher S. Muratore, MD	Stony Brook Children’s Hospital
Elizabeth O’Hare, BS	Johns Hopkins University, Baltimore
Erin E. Perrone, MD	University of Michigan, Fetal Diagnosis and Treatment Center
David T. Schindel, MD	UT Southwestern Medical Center, Dallas
Niti Shahi, MD	University of Massachusetts & Children’s Hospital of Colorado
Eveline H. Shue, MD	Children’s Hospital of Los Angeles, Los Angeles
David H. Stitelman, MD	Yale – New Haven Children’s Hospital
Shaheen Timmapuri, MD	Rutger’s – RWJ Medical School, New Brunswick
Amy J. Wagner, MD	Children’s Hospital of Wisconsin, Milwaukee
Michael V. Zaretsky, MD	Children’s Hospital of Colorado, Colorado Fetal Care Center
Abdalla E. Zarroug, MD	Sidra Medicine

## TABLE OF CONTENTS

	List of contributors	i
	Acknowledgements	i
	Foreword	ii
	Table of Contents	iii
Chapter 1	History and Overview of Maternal-Fetal Surgery	1
Chapter 2	Congenital Lung Lesions	4
Chapter 3	Congenital Diaphragmatic Hernia	14
Chapter 4	Sacroccygeal Teratoma	27
Chapter 5	Fetal Masses and Neoplasms	31
Chapter 6	Myelomeningocele	37
Chapter 7	Abdominal Wall Defects	47
Chapter 8	Intestinal Obstruction, Atresias and Abdominal Cysts	55
Chapter 9	Twin Gestations and Twin-to-Twin Transfusion Syndrome	65
Chapter 10	Fetal Airway	76
Chapter 11	Anomalies of the Genitourinary Tract	82

## The Evolution of Maternal-Fetal Surgery

Eveline H. Shue, Sundeep G. Keswani and Shinjiro Hirose

Fetal intervention for congenital anomalies has evolved over the past three decades from a conceptual thought to a full-fledged multidisciplinary medical specialty. Advances in fetal imaging and diagnosis have increasingly allowed clinicians to accurately identify complex anomalies prenatally and stratify the severity of disease. Data that has been accrued over the past three decades provides expectant families with information about the natural history and outcomes of specific disorders, allowing families to make informed decisions about pregnancy and delivery plans. In select cases, fetal intervention can be considered to prevent the progressive organ damage that occurs from congenital anomalies.

Results from early experiences with fetal therapy generated a movement away from anatomic repair of congenital anomalies to physiologic manipulation of the developmental consequences (e.g., the shift from *in utero* repair of the CDH defect to balloon tracheal occlusion to promote lung growth). Techniques used in fetal intervention have also evolved from maximally invasive (e.g., open hysterotomy) to more minimally invasive interventions, such as fetal endoscopy, and image-guided percutaneous procedures. Innovation in surgical tools and techniques have led to the development of minimally invasive surgery (MIS) techniques for diseases. The promise of fetal MIS techniques has many advantages: (1) a reduction in the risk of uterine wound healing issues, (2) a reduction in the need for cesarean deliveries and (3) a reduction in the risk of preterm labor, previously the “Achilles heel” of fetal surgery. These advances have been paralleled by innovations in fetal imaging, fetal genetic diagnosis and the development of new effective maternal tocolytic strategies to prevent preterm labor. The future looks equally bright with promising research advancing the concept of gene and cellular therapy as a new horizon in fetal-stage treatment of disease. Fetal intervention has evolved into an important option for fetuses who would otherwise not survive gestation or who would endure significant morbidity and mortality after birth.

As the fetal surgery community amasses experience with fetal intervention, an emphasis has been placed on randomized controlled trials instead of retrospective clinical trials. In 1982, the International Fetal Medicine and Surgery Society (IFMSS) held its first annual meeting. This society continues to be an important international venue. In the 1990s, trials for fetal intervention were being performed in many different fetal treatment centers across the world. In 2005, a cooperative clinical research network, the North American Fetal Therapy Network (NAFTNet), was formed to promote multi-institutional trials in the United States and Canada to study fetal disease, develop prenatal interventions and improve outcomes. Similarly, the Eurofoetus group was formed in Europe to promote multicenter clinical trials and foster innovation in fetal medicine. These international organizations of obstetricians, surgeons, perinatologists and sonologists were formed with an overarching goal to promote maternal safety while improving outcomes for patients with fetal anomalies.

Institutional centers dedicated to fetal treatment require a collaborative team of specialists who are dedicated to continuity of care for both the mother and the fetus. A successful and productive fetal treatment program is a collaborative, multidisciplinary team, which includes an obstetrician,

perinatologist, geneticist, sonologist, surgeon, neonatologist and anesthesiologist, in addition to experienced support personnel (Table 1). The obstetrician, who is an expert in prenatal diagnosis, amniocentesis, chorionic villus sampling, complications of pregnancy and family counseling, is important for management of the pregnancy. Pediatric surgeons and neonatologists, who understand the pathophysiology behind neonatal diseases and their treatment after birth, are important for developing a therapeutic plan. The skills of an obstetric sonographer and pediatric radiologist are also invaluable in delineating the fetal anomaly and in guiding diagnostic and therapeutic interventions. If fetal surgical therapies are being offered, an anesthesiologist that is trained in the nuances of providing anesthesia for both the mother and the fetus is essential. Furthermore, in today's rapidly developing field of prenatal genetics, a qualified genetics counselor is an indispensable partner in the fetal team. In specific fetal anomalies, a pediatric cardiologist, neurologist, nephrologist, neurosurgeon, or endocrinologist are also highly valuable to provide the full spectrum of fetal diagnosis and therapy.

The key to the success of this multidisciplinary team is effective collaboration and communication. These interactions should be formalized with a weekly multidisciplinary meeting, where patients are discussed in depth and plans are formulated among all specialists and personnel involved. Through these weekly interactions, care plans and interventions are mapped with consensus across all disciplines. This is the model for most of the major fetal treatment centers in the United States. However, the field has evolved, and with the ease of accessibility to information for the general public, it is imperative that all pediatric surgeons have a fundamental knowledge of prenatal diagnosis, natural history and options for fetal intervention to provide patients with the necessary information or to refer patients to fetal centers, so that families can make appropriate decisions.

A close working relationship between perinatal specialists is crucial to success in a fetal treatment program. However, the institution also needs to be adequately equipped to care for fetal patients. Together this requires a high-risk obstetric unit with obstetricians who are available around the clock and have experience delivering patients with a recent hysterotomy, a Level III C neonatal intensive care unit and an environment where research is combined with clinical care. Because fetal intervention is a new frontier, experience, success and failure must be critically analyzed, documented and shared to improve patient care and improve understanding.

Over the past 30 years, fetal surgery has evolved into a multidisciplinary, collaborative medical specialty that strives to improve outcomes in patients diagnosed with fetal anomalies. Physicians dedicated to fetal medicine and fetal surgery have formed a cooperative community dedicated to reporting both good and poor outcomes from fetal intervention. Through these collaborations, several multicenter, randomized, controlled clinical trials have been successfully completed. This frontier could not have been established without dedicated physicians, support staff and institutional support, and this strong foundation will serve as the platform for the effective advancement of this "new" field of Maternal-Fetal Surgery.

**Table 1: Basic Components of the Fetal Care Team**

- Designated team leader
- Care coordinator
- Pediatric cardiologist to perform fetal echocardiogram
- Fetal surgeon – usually a pediatric surgeon or a perinatologist
- Genetic counselor
- Pediatric radiologist to interpret fetal MRI
- Maternal fetal medicine specialist
- Neonatologist
- Obstetric anesthetist
- Pediatric anesthetist
- Social worker
- Ultrasonologist

## Congenital Lung Lesions

Mitchell R. Ladd, Timothy Lee, and Eric B. Jelin

### Introduction

Congenital lung lesions (CLL) comprise a diverse spectrum of pathologic conditions. These conditions range from small cystic lung lesions that are asymptomatic to large lesions which may lead to a lethal outcome in utero. Broadly, CLLs can be broken down into bronchial lesions and cystic lung lesions. While there are numerous rare diseases in both categories, the most common bronchial lesions are bronchial atresia and bronchogenic cysts while the most common cystic lung lesions are congenital pulmonary airway malformation (CPAM) and bronchopulmonary sequestration (BPS) [1]. Many of these lesions arise along a spectrum of developmental pathways with the most common being CPAM. CPAM was formerly termed cystic adenomatoid malformation (CCAM) but CPAM is now the preferred nomenclature. In addition, hybrid lesions that consist of a CPAM with a component of bronchial atresia or aspects of BPS exist as well [1]. Other rare lesions such as bronchial isomerism, bronchial stenosis, broncho-biliary fistula, congenital hyperinflation syndromes, pleuropulmonary blastoma and fetal lung interstitial tumors are outside of the scope of this review (for an excellent review on many of these lesions, the reader is referred to Fowler and Gould [1]). The diagnosis and management of these lesions may be challenging in the prenatal period, and some may require urgent fetal intervention. An understanding of the pathology and treatment strategies is critical in the prenatal management of these patients.

### Pathophysiology of CLLs

#### *Congenital Pulmonary Airway Malformation (CPAM)*

CPAMs are developmental lung malformations that form as a result of abnormal branching during lung morphogenesis and lead to an abnormal airway pattern with possible cystic or adenomatous areas [2]. CPAMs have a connection to the tracheobronchial tree and the vascular supply arises from the pulmonary arterial system. The prevalence of CPAMs has been estimated by a European registry to be 1.02 per 10,000 live births [3] however the incidence has been reported to be as high 1 in 1,980 live births [4]. CPAMs are the most common congenital lung malformation (30-40%) [2].

There are two theories for how CPAMs form: the environmental hypothesis and the obstructive hypothesis [2]. In the environmental hypothesis, CPAMs develop as a result of the persistent expression of early lung developmental genes, that lead to interruptions in lung formation [2]. For an excellent review of lung morphogenesis and the potential genes involved in lung morphogenesis and CPAMs, the reader is directed to Leblanc et al. [2]. The obstructive hypothesis proposes that a focal obstruction of the airway, whether functional (i.e. a peristaltic anomaly) or



a true stenosis (as seen in bronchial stenosis), cause abnormal gene expression and subsequently disrupted lung morphogenesis [2].

The natural history of congenital lung lesions can be quite variable. CPAMs usually arise from a single lobe, but rarely can affect multiple lobes or both lungs. There does not seem to be a predilection for either side of the lung, but they seem to occur slightly more often in the lower lobes [4]. CPAMs occur in both sexes and all ethnicities equally [4]. While it was previously thought that nearly 100% of CPAMs are diagnosed on prenatal ultrasound by 18-20 weeks of gestation [4], a recent study by Mon et al. demonstrated that ultrasound only detected 82.5% of fetal lung lesions (which included CPAMs, BPS, and other fetal lung lesions) and correctly diagnosed CPAM in 75% of cases (sensitivity 93% but specificity of 32%) [5]. These lesions may have an unpredictable growth pattern from 18 to 26 weeks of gestation [6,7]. Various reports have noted that over the first 28 weeks of gestation that 11-49% will disappear, 18-42% shrink, and 33-44% enlarge [2,8–11]. Lesions that disappear prenatally may still be present at birth in an estimated 55.3-60% and should be evaluated with imaging postnatally [2,8,12]. Lesions that disappear completely tend to be microcystic, low volume, and are often less symptomatic at birth compared to those lesions that persist on prenatal imaging [2,12].

In regard to classification, the original Stocker classification system stratified these lesions from type 1 to type 3 based on cyst size (Type 1 are large cysts 3-10 cm in size, Type 2 are medium cysts 0.5-2 cm in size, and type 3 are very small cysts less than 0.2 cm in size) [1,13]. The new classification system includes the original types (1-3) and adds types 0 and 4 (Type 0 are acinar dysplasia, usually bilateral, small firm lungs, and are incompatible with life, Type 4 are peripheral cysts) [1,13]. The relevance of this classification in clinical decision making is minimal. A more relevant classification system is to classify the cysts prenatally as macrocystic (>5 mm in diameter for single or multiple cysts) or microcystic (<5 mm) [14,15]. The clinical relevance of this classification system lies in the differing fetal treatment options and outcomes for these pulmonary lesions [15].

### *Bronchopulmonary Sequestration*

Pulmonary sequestrations are areas of non-functioning lung which have no connection to the bronchial tree. These lesions possess a systemic arterial blood supply which often arises from the aorta, and the venous drainage may drain into the pulmonary veins, the azygous system, or the inferior vena cava [16]. BPS accounts for approximately 6% of congenital lung anomalies and can be classified as intralobar (15%) or extralobar (85%) [16]. Both types of BPS occur slightly more commonly on the left side [1,16]. An intralobar sequestration is located within the lung parenchyma and has pulmonary venous return, while the extralobar sequestration is separate from the lung, has systemic venous return, and has a separate pleural covering. Most extralobar sequestrations are found within the thoracic cavity, but in rare cases can be found within or below the diaphragm [16,17]. The main theory for how BPS develops is as a result of an accessory lung bud [16,18]. The existence of hybrid CLLs which share characteristics of both BPS and CPAM

suggest that these two pathologic entities share an embryologic origin. In other words, in hybrid lesions bronchial atresia may result in a sequestration with adenomatoid change [1].

Most BPS lesions are diagnosed prenatally. For extralobar sequestrations, if not diagnosed prenatally, most patients present within the first 6 months of life [16]. Extralobar sequestrations are frequently associated with cardiac anomalies, but the most common associated anomaly is diaphragmatic hernia. Other anomalies include tracheoesophageal fistula and esophageal duplication [19]. Intralobar sequestrations usually present after the age of 2 with chronic pneumonia if they are not detected prenatally [16]. Intralobar sequestrations most commonly affect the medial and posterior basal segments of the lower lobes [16].

### *Bronchial Atresia*

Bronchial atresia is characterized by stenosis of the bronchus at any level within the bronchial tree. Due to the stenosis, the distal lung develops progressive mucostasis and hyperinflation. The pathology of bronchial atresia has been hypothesized to be due a vascular insult to the bronchus [18]; however, no definitive pathologic pathway has been proven. The increasing frequency of this diagnosis has been felt to be due to the increased use of prenatal imaging and the fact that these lesions are often associated with other pulmonary malformations such as CPAMs or BPS. Kunisaki et al. demonstrated that bronchial atresia was present in as many as 77% of prenatally diagnosed CLLs [20]. In isolation, bronchial atresia will rarely need fetal intervention; however, mainstem bronchial atresia has been described as a fatal process. Keswani *et al.* reported two cases where both fetuses died, one during an open fetal pneumonectomy [21].

### **Fetal Imaging for CLLs**

The diagnosis and characterization of congenital lung lesion are made primarily by the use of prenatal ultrasound. The initial categorization of CLLs is as a solid or cystic mass. Cystic lesions are further classified as macrocystic, microcystic, or hybrid lesions. Sequestrations appear as a solid, echogenic lesion. Using Doppler, the systemic feeding vessel can often be identified in these lesions.

A recent study by Mon et al. compared prenatal ultrasound and magnetic resonance imaging (MRI) to postnatal computerized tomography (CT) scan [5]. They showed that prenatal ultrasound detected 82.5% of CLLs [5]. However, ultrasound was inaccurate in predicting histology in 25% of CLLs and poor sensitivity for detecting feeding vessels for BPS (only 49% sensitivity) [5]. Fetal MRI had a similar ability to predict histology (27% inaccurate) but better sensitivity for detecting feeding vessels (sensitivity of 71%) [5]. In contrast, postnatal CT scan diagnosis (the current gold standard for CLLs) was discordant with histology in only 16.5% of cases with sensitivity for feeding vessels of 93% [5]. Of note, while Mon et al. highlighted the benefits of obtaining a fetal MRI for CLLs (i.e. further anatomic information can be obtained, it can better identify feeding vessels, and it is not limited by maternal body habitus or fetal position), the authors note that in their

series, it did not change prenatal decision making in any cases [5]. Thus, decisions regarding the utility of fetal MRI and fetal echocardiogram are based on the interpretation of the ultrasound.

Despite numerous ultrasound characteristics that have been studied to predict the outcome of fetuses with CLL, in particular the presence of mediastinal shift, microcystic vs. macrocystic disease, presence of fetal hydrops, and the mass size typically in the form of congenital pulmonary airway malformation volume ratio (CVR), only two have demonstrated consistent prognostic value: CVR and the presence of fetal hydrops. CVR, which is discussed in more detail in the next section, is used to predict outcome of fetuses with CLL and to attempt to predict those that will go on to develop fetal hydrops and/or need fetal intervention. Fetal hydrops is defined as the accumulation of fluid within two or more body cavities (ascites, pleural effusion, pericardial effusion or skin/scalp edema). Hydrops is often a harbinger of poor fetal or postnatal outcomes and the development of fetal hydrops in the setting of CLL is almost universally fatal without treatment [22]. Once a CLL is discovered, it should be characterized to determine whether it is macrocystic vs. microcystic, the CVR should be calculated, and the fetus should be evaluated for hydrops [23]. The fetus should additionally be evaluated for other effects of the CLL (such as pleural effusions or cardiac effects) and any other associated anomalies using ultrasound, echocardiography, or fetal MRI as appropriate [23]. Abnormal fetal echocardiogram findings can be defined as increased or decreased combined cardiac output, ventricular hypertrophy, atrial or ventricular chamber dilation, cardiomegaly, significant valvular regurgitation, diastolic dysfunction or findings of heart failure. Finally, the presence of placentomegaly (>5 cm in thickness) can be a harbinger of imminent in utero demise.

### **Congenital Pulmonary Airway Malformation Volume Ratio (CVR)**

The CVR has emerged as one of the most useful tools in predicting outcomes in prenatally diagnosed pulmonary lesions. The CVR is a measurement of cyst volume and is calculated by using ultrasound to measure the pulmonary lesion in 3 dimensions (length, width, height) followed by calculating the volume of the cyst using the formula for a prolate ellipse ( $L \times W \times H \times 0.52$ ) [24]. The volume is then divided by the head circumference to normalize for gestational age. The full equation is:  $(L \times W \times H \times 0.52 / \text{head circumference})$  and a larger number correlates with a worse prognosis. The initial report by Crombelehme et al documented that 80% of fetuses with a  $\text{CVR} > 1.6$  upon initial evaluation went on to develop hydrops [25]. Another study described a similar predictive value of CVR, but with a cutoff of 2.0 [24]. In this series, 56% of fetuses with  $\text{CVR} > 2.0$  required prenatal intervention compared to 3% of the fetuses with a  $\text{CVR} < 2.0$ . CVR has also been used to predict which fetuses would be at risk for respiratory compromise at birth and thus which fetuses with CLL should be delivered at a tertiary care center [26]. Ehrenberg-Buchner et al. found, when using CVR to characterize all echogenic pulmonary masses, that fetuses with a maximum CVR greater than 1 had a 75% risk of having respiratory symptoms at birth that would require surgical resection and that in those fetuses with maximum CVR less than one, a nearly 100% probability of being asymptomatic at birth [26]. Thus, the authors recommended that all fetal lung lesions without hydrops be followed with ultrasound every 2 weeks until the CVR is stable or declining [26]. Afterwards, in stable lesions with CVR less than 1, scanning can be less frequent (such as every 4 weeks). In addition, maximum CVR should

be used to determine need for delivery at a tertiary care center. Thus, they recommend that any fetus with a history of hydrops or maximum CVR greater than 1 be delivered at a tertiary care center. Otherwise, the fetus can be delivered in the community hospital with pediatric surgery follow up at a later date [26]. Clearly, the CVR is a useful prognostic tool for CLLs which is continuing to be studied and refined.

### **Fetal Surveillance and Therapy**

There are no absolute criteria for fetal intervention; however, several guidelines exist and fetal therapy is reserved for only the most severe congenital lung lesions (i.e., presence of hydrops, expected significant respiratory distress at birth, or high risk of in utero demise). Other indications for intervention include a large dominant cyst (>2cm) with concern for sudden expansion and distorted anatomy that is likely to obstruct the airway. Smaller (CVR <2.0) lesions or asymptomatic (non-hydrops) larger lesions can be safely followed with weekly ultrasounds. Because certain CLLs can undergo rapid expansion up to 28 weeks, this is a crucial time period to consider closer monitoring for any changes in the baby's physiologic status. As mentioned above, a recent recommendation on follow up is to do ultrasound scans every 2 weeks until the CVR stabilizes or declines and then perform monthly scanning thereafter [26]. In this setting, any history of hydrops or a maximum CVR greater than 1 should prompt referral to a tertiary care center for delivery. In general, invasive fetal interventions (thoraco-amniotic shunts or fetal resection) are performed only for fetuses that are less than 32 weeks of gestation that have not responded to steroid therapy. Hydropic fetuses that are greater than 32 weeks of gestation should be delivered with a plan for urgent resection [27].

### **Maternal Mirror Syndrome**

A fetus with a large lung mass that has developed hydrops and placentomegaly may also place the mother at significant risk for maternal mirror syndrome [6]. Mirror syndrome is a maternal complication which results in the mother's health state mirroring that of the fetus. The mother can develop symptoms such as hypertension, vomiting, pulmonary edema and proteinuria. Untreated, these symptoms can progress in severity and can potentially threaten the life of the mother. The only treatment for the severe form of this syndrome is delivery of the baby [28].

### **Minimally Invasive Approaches to Congenital Lung Lesions**

#### *Maternal Steroids (Betamethasone)*

The initial intervention that should be considered in fetuses less than 32 weeks of gestation with large (CVR > 1.6), symptomatic (i.e. hydropic fetuses) solid or microcystic CLLs is the administration of prenatal steroids. This therapy has been described in several case series, yielding a variable but definite response [15,27,29,30]. Although there are currently no definitive recommendations and no conclusive data to support the use of prenatal steroids for symptomatic CLLs, several centers have independently noted lesion regression and hydrops reversal after administration. The administration of steroids is a two-dose maternal regimen of

betamethasone given 24 hours apart. A recent series evaluated the effect of multiple course of betamethasone and found that treatment with multiple courses (2 and 3 courses) had less reduction in size of the lesions but similar survival to those that received only one course [15]. Those that required multiple courses and failed to respond indicated the presence of a lesion that would require fetal or immediate neonatal resection[15]. The exact mechanism as to how betamethasone induces lesion regression is not clearly defined, but it has been proposed that steroids stimulate the maturation of lung cells or perhaps that it affects cell proliferation and apoptosis therefore slowing CPAM growth [23,29]. Unfortunately, steroids have proven less effective in the resolution of macrocystic lesions which typically require cyst drainage or fetal resection [22].

### *Cyst Drainage*

For fetuses less than 32 weeks of gestation with large, symptomatic macrocystic disease, most centers would employ a minimally invasive approach to decompress the large lesions. This can be accomplished via ultrasound-guided cyst aspiration or deployment of a thoraco-amniotic shunt. Cyst aspiration quickly reduces the volume of a macrocystic lesion; however, it is frequently only a temporizing solution, as re-accumulation of the fluid within 48-72 hours is common. The use of a thoraco-amniotic shunt has been described with excellent survival rates in patients with macrocystic disease [31,32]. Practically, shunt dislodgement after placement is a common phenomenon (occurs in 40% of cases usually caused by the fetal movement) that may necessitate a repeat procedure [33]. Of note, shunting is ideally performed after 20 weeks of gestation to reduce the risk of chest wall deformity[23]. Shunting has also been used for BPS with tension hydrothorax to prevent pulmonary hypoplasia and cardiac compromise [22].

### *Open Fetal Surgery and EX Utero Intra Partum Treatment (EXIT):*

Open fetal surgery has been employed for resection of prenatally diagnosed high-risk lung lesions and can be offered when there is impending fetal demise. These procedures are considered on a case-by-case basis for fetuses with solid lung lesions and hydrops that have not improved with betamethasone and are usually offered prior to 30 weeks of gestation [22]. Candidates for fetal surgery must typically meet strict maternal and fetal criteria which include a normal fetal karyotype and no other anatomic abnormalities [22]. For a full list of maternal and fetal criteria refer to Khalek et al. [22]. In patients greater than 32 weeks of gestation with hydrops, EXIT to resection may be the optimal pathway [22]. The rationale for this approach is that positive pressure ventilation may increase the size of the mass leading to worsening of cardiac compression and cardiovascular collapse. The resection of the chest mass, while on placental support, prevents mass inflation.

### **Postnatal Management of CLLs**

It is well accepted that symptomatic CLLs should be resected, but there is some debate about asymptomatic CLLs [23]. Most centers advocate elective and early resection of asymptomatic CLLs based on several arguments: early lobectomy avoids repeated exposure to radiation for

surveillance, imaging cannot definitively determine the pathologic diagnosis, if the lesion is a CPAM there is a risk of future malignant transformation, and early resection allows for better compensatory lung growth, especially if performed before 1 year of life [23]. In addition, if asymptomatic lesions become symptomatic with recurrent infections, the eventual operation may be more difficult [23]. Thus, most surgeons agree that resection of CLLs should be done during the first year of life. While some advocate waiting until 6 months for resection, a recent retrospective study demonstrated that resection of CPAMs is equally safe in all ages from 1 month to 12 months, but that resection at earlier ages had decreased operative times [23,34]. The operation of choice for CLLs is lobectomy of the affected lobe [23]. Open or thoracoscopic lobectomy are equally effective and the choice of approach is based on surgeon experience, although the thoracoscopic approach tends to have a shorter hospital stay, better cosmesis, and less postoperative pain [23].

### **Level of Evidence**

Grade B, Level 3a/3b (case-control studies)

## References

- [1] D.J. Fowler, S.J. Gould, The pathology of congenital lung lesions, *Semin. Pediatr. Surg.* 24 (2015) 176–182. doi:10.1053/j.sempedsurg.2015.02.002.
- [2] C. Leblanc, M. Baron, E. Desselas, M.H. Phan, A. Rybak, G. Thouvenin, C. Lauby, S. Irtan, Congenital pulmonary airway malformations: state-of-the-art review for pediatrician's use, *Eur. J. Pediatr.* 176 (2017) 1559–1571. doi:10.1007/s00431-017-3032-7.
- [3] EUROCAT, (n.d.). <http://www.eurocat-network.eu/accessprevalencedata/prevalencetables> (accessed August 6, 2018).
- [4] K. Lakhoo, Management of congenital cystic adenomatous malformations of the lung, *Arch. Dis. Child. Fetal Neonatal Ed.* 94 (2009) 73–76. doi:10.1136/adc.2007.130542.
- [5] R.A. Mon, K.N. Johnson, M. Ladino-Torres, A. Heider, G.B. Mychaliska, M.C. Treadwell, S.M. Kunisaki, Diagnostic accuracy of imaging studies in congenital lung malformations, *Arch. Dis. Child. - Fetal Neonatal Ed.* (2018) fetalneonatal-2018-314979. doi:10.1136/archdischild-2018-314979.
- [6] N.S. Adzick, M.R. Harrison, T.M. Crombleholme, A.W. Flake, L.J. Howell, Fetal lung lesions: Management and outcome, *Am. J. Obstet. Gynecol.* 179 (1998) 884–889. doi:10.1016/S0002-9378(98)70183-8.
- [7] D. Bianchi, T. Crombleholme, M. D'Alton, Cystic adenomatoid malformation, in: D. Bianchi, T. Crombleholme, M. D'Alton (Eds.), *Fetology Diagnosis Manag. Fetal Patient*, McGraw-Hill, New York, 2000.
- [8] P. Cavoretto, F. Molina, S. Poggi, M. Davenport, K.H. Nicolaides, Prenatal diagnosis and outcome of echogenic fetal lung lesions, *Ultrasound Obstet. Gynecol.* 32 (2008) 769–783. doi:10.1002/uog.6218.
- [9] M. Stanton, I. Njere, N. Ade-Ajayi, S. Patel, M. Davenport, Systematic review and meta-analysis of the postnatal management of congenital cystic lung lesions, *J. Pediatr. Surg.* 44 (2009) 1027–1033. doi:10.1016/j.jpedsurg.2008.10.118.
- [10] A. Hadchouel, A. Benachi, Y. Revillon, V. Rousseau, J. Martinovic, V. Verkarre, Y. Dumez, C. Delacourt, Factors associated with partial and complete regression of fetal lung lesions, *Ultrasound Obstet. Gynecol.* 38 (2011) 88–93. doi:10.1002/uog.8909.
- [11] J.S. Lima, P.A.M. Camargos, R.A.L.P. Aguiar, A.S. Campos, M.J.B. Aguiar, Pre and perinatal aspects of congenital cystic adenomatoid malformation of the lung, *J. Matern. Neonatal Med.* 27 (2014) 228–232. doi:10.3109/14767058.2013.807236.
- [12] S.M. Kunisaki, S. Ehrenberg-Buchner, J.R. Dillman, E.A. Smith, G.B. Mychaliska, M.C. Treadwell, Vanishing fetal lung malformations: Prenatal sonographic characteristics and postnatal outcomes, *J. Pediatr. Surg.* 50 (2015) 978–982. doi:10.1016/j.jpedsurg.2015.03.025.
- [13] STOCKER, J.T., Congenital pulmonary airway malformation : a new name and expanded classification of congenital cystic adenomatoid malformation of the lung, *Histopathology.* 41 (2002) 424–431. <https://ci.nii.ac.jp/naid/10029090425/> (accessed July 26, 2018).
- [14] N.S. Adzick, M.R. Harrison, P.L. Glick, M.S. Golbus, R.L. Anderson, B.S. Mahony, P.W. Callen, J.H. Hirsch, D.A. Luthy, R.A. Filly, Fetal cystic adenomatoid malformation: prenatal diagnosis and natural history., *J. Pediatr. Surg.* 20 (1985) 483–8. <http://www.ncbi.nlm.nih.gov/pubmed/3903097> (accessed August 11, 2018).
- [15] W.H. Peranteau, M.M. Boelig, N. Khalek, J.S. Moldenhauer, J. Martinez-Poyer, H.L. Hedrick, A.W. Flake, M.P. Johnson, N.S. Adzick, Effect of single and multiple courses of maternal betamethasone on prenatal congenital lung lesion growth and fetal survival, *J. Pediatr. Surg.* 51 (2016) 28–32. doi:10.1016/j.jpedsurg.2015.10.018.
- [16] J. Durell, K. Lakhoo, Congenital cystic lesions of the lung, *Early Hum. Dev.* 90 (2014) 935–939.

- doi:10.1016/j.earlhumdev.2014.09.014.
- [17] A. Nijagal, E. Jelin, V.A. Feldstein, J. Courtier, A. Urisman, K.D. Jones, H. Lee, S. Hirose, T.C. MacKenzie, The diagnosis and management of intradiaphragmatic extralobar pulmonary sequestrations: A report of 4 cases, *J. Pediatr. Surg.* 47 (2012) 1501–1505. doi:10.1016/j.jpedsurg.2011.11.066.
- [18] C. Langston, New concepts in the pathology of congenital lung malformations., *Semin. Pediatr. Surg.* 12 (2003) 17–37. doi:10.1053/spsu.2003.00001.
- [19] K. Gajewska-Knapik, L. Impey, Congenital lung lesions: Prenatal diagnosis and intervention, *Semin. Pediatr. Surg.* 24 (2015) 156–159. doi:10.1053/j.sempedsurg.2015.01.012.
- [20] S.M. Kunisaki, D.O. Fauza, L.P. Nemes, C.E. Barnewolt, J.A. Estroff, H.P. Kozakewich, R.W. Jennings, Bronchial atresia: The hidden pathology within a spectrum of prenatally diagnosed lung masses, *J. Pediatr. Surg.* 41 (2006) 61–65. doi:10.1016/j.jpedsurg.2005.10.082.
- [21] S.G. Keswani, M.P. Johnson, B.R. Pawel, T.M. Crombleholme, A.W. Flake, H.L. Hedrick, L.J. Howell, R.D. Wilson, G.H. Davis, N.S. Adzick, Prenatal diagnosis and management of mainstem bronchial atresia, *Fetal Diagn. Ther.* 20 (2005) 74–78. doi:10.1159/000081374.
- [22] N. Khalek, M.P. Johnson, Management of prenatally diagnosed lung lesions, *Semin. Pediatr. Surg.* 22 (2013) 24–29. doi:10.1053/j.sempedsurg.2012.10.005.
- [23] M. David, R. Lamas-Pinheiro, T. Henriques-Coelho, Prenatal and Postnatal Management of Congenital Pulmonary Airway Malformation, *Neonatology.* 110 (2016) 101–115. doi:10.1159/000440894.
- [24] D.L. Cass, O.O. Olutoye, C.I. Cassady, K.J. Moise, A. Johnson, R. Papanna, D.A. Lazar, N.A. Ayres, B. Belleza-Bascon, Prenatal diagnosis and outcome of fetal lung masses, *J. Pediatr. Surg.* 46 (2011) 292–298. doi:10.1016/j.jpedsurg.2010.11.004.
- [25] T.M. Crombleholme, B. Coleman, H. Hedrick, K. Liechty, L. Howell, A.W. Flake, M. Johnson, N.S. Adzick, Cystic adenomatoid malformation volume ratio predicts outcome in prenatally diagnosed cystic adenomatoid malformation of the lung., *J. Pediatr. Surg.* 37 (2002) 331–8. <http://www.ncbi.nlm.nih.gov/pubmed/11877643> (accessed July 26, 2018).
- [26] S. Ehrenberg-Buchner, A.M. Stapf, D.R. Berman, R.A. Drongowski, G.B. Mychaliska, M.C. Treadwell, S.M. Kunisaki, Fetal lung lesions: Can we start to breathe easier?, *Am. J. Obstet. Gynecol.* 208 (2013) 151.e1-151.e7. doi:10.1016/j.ajog.2012.11.012.
- [27] W.H. Peranteau, R.D. Wilson, K.W. Liechty, M.P. Johnson, M.W. Bebbington, H.L. Hedrick, A.W. Flake, N.S. Adzick, Effect of maternal betamethasone administration on prenatal congenital cystic adenomatoid malformation growth and fetal survival, *Fetal Diagn. Ther.* 22 (2007) 365–371. doi:10.1159/000103298.
- [28] T. Braun, M. Brauer, I. Fuchs, C. Czernik, J.W. Dudenhausen, W. Henrich, N. Sarioglu, Mirror syndrome: A systematic review of fetal associated conditions, maternal presentation and perinatal outcome, *Fetal Diagn. Ther.* 27 (2010) 191–203. doi:10.1159/000305096.
- [29] P.F. Curran, E.B. Jelin, L. Rand, S. Hirose, V.A. Feldstein, R.B. Goldstein, H. Lee, Prenatal steroids for microcystic congenital cystic adenomatoid malformations., *J. Pediatr. Surg.* 45 (2010) 145–50. doi:10.1016/j.jpedsurg.2009.10.025.
- [30] K.C. Loh, E. Jelin, S. Hirose, V. Feldstein, R. Goldstein, H. Lee, Microcystic congenital pulmonary airway malformation with hydrops fetalis: Steroids vs open fetal resection, *J. Pediatr. Surg.* 47 (2012) 36–39. doi:10.1016/j.jpedsurg.2011.10.015.
- [31] R.D. Wilson, J.K. Baxter, M.P. Johnson, M. King, S. Kasperski, T.M. Crombleholme, A.W. Flake, H.L. Hedrick, L.J. Howell, N.S. Adzick, Thoracoamniotic shunts: Fetal treatment of pleural effusions and congenital cystic adenomatoid malformations, *Fetal Diagn. Ther.* 19 (2004) 413–420. doi:10.1159/000078994.
- [32] S. Schrey, E.N. Kelly, J.C. Langer, G.A. Davies, R. Windrim, P.G.R. Seaward, G. Ryan, Fetal



- thoracoamniotic shunting for large macrocystic congenital cystic adenomatoid malformations of the lung, *Ultrasound Obstet. Gynecol.* 39 (2012) 515–520. doi:10.1002/uog.11084.
- [33] R.A. Mon, M.C. Treadwell, D.R. Berman, L. Day, J. Kreuzman, G.B. Mychaliska, E.E. Perrone, Outcomes of fetuses with primary hydrothorax that undergo prenatal intervention (prenatal intervention for hydrothorax)., *J. Surg. Res.* 221 (2018) 121–127. doi:10.1016/j.jss.2017.08.034.
- [34] E.B. Jelin, E.M. O’Hare, T. Jancelewicz, I. Nasr, E. Boss, D.S. Rhee, Optimal timing for elective resection of asymptomatic congenital pulmonary airway malformations, *J. Pediatr. Surg.* 53 (2018) 1001–1005. doi:10.1016/j.jpedsurg.2018.02.032.

## **Congenital Diaphragmatic Hernia**

**Amanda R. Jensen, Corey W. Iqbal, Erin E. Perrone**

### **Introduction**

The incidence of congenital diaphragmatic hernia (CDH) is estimated between 1 in 2,200 to 5,000 live births [1, 2]; however the true incidence is likely closer to 1 in 2,200 as this defect can be associated with intra-uterine fetal demise and stillbirth which is difficult to capture in epidemiologic studies [2, 3]. Determining an accurate mortality rate for CDH is also a moving target given the variable referral patterns that tend to triage sicker babies to tertiary referral centers. The best available estimates have reported mortality rates as high as 75% for prenatally diagnosed CDH [4, 5]. Most other estimates put the mortality rate around 50% [4-6]. CDH is being more commonly diagnosed antenatally (usually by 25 weeks gestation) with early prenatal care, enhanced imaging modalities and a heightened awareness of findings associated with CDH. These are typically posterolateral defects in the diaphragm with 85-90% located on the left, 10-15% located on the right, and a very small percentage located bilaterally [2]. While advances in medical management of CDH have improved outcomes in the last century, our ability for prenatal diagnosis of CDH has not affected the grim prognosis associated with defects that result in fatal pulmonary hypoplasia and pulmonary hypertension but allows for prenatal triaging of the most severe cases for potential fetal intervention and preparedness for the postnatal transition.

The role of fetal intervention for CDH is still an area of intense investigation and currently is not widely available; however, the pediatric surgeon will be asked to counsel families caring for pregnancies complicated by CDH. The diagnosis of CDH has significant immediate implications for the family regarding delivery at a tertiary referral center, the need for neonatal intensive care, the decision for extra-corporeal membranous oxygenation (ECMO) support, and other aggressive resuscitative measures. With a life threatening diagnosis such as CDH, termination of pregnancy may be considered and comfort with that topic is essential. Therefore, it is critical that pediatric surgeons are capable of interpreting antenatal studies and counseling families so they can make informed decisions regarding the pregnancy.

### **Diagnostic Modalities and Prognostic Indicators**

#### *Fetal Ultrasonography*

Ultrasonography (US) is routinely performed during the prenatal period. Polyhydramnios has been implicated in CDH from anatomic obstruction of the displaced stomach, as well as mediastinal compression on the esophagus impairing the fetus' ability to swallow amniotic fluid [7]. Once the suspicion for CDH has been raised, a more thorough investigation of the thorax can be undertaken to identify herniated abdominal contents. It is widely accepted that the

presence of abdominal structures seen at the same level as the four-chamber heart view on US confirms the presence of a diaphragmatic hernia [1]. Abdominal viscera, visualized above the tip of the scapula, can also be used as a reference point [1]. In some cases, US can visualize the defect in the diaphragm, making the diagnosis very clear.

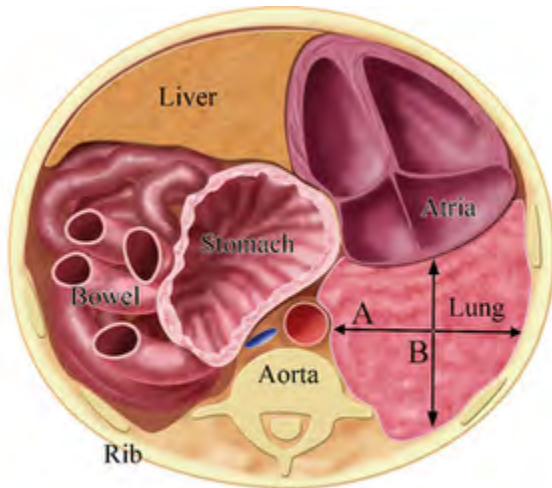
The presence of liver herniation reproducibly predicts a worse outcome for CDH [8, 9]; therefore, position of the fetal liver should be assessed during fetal US. Kinking of the sinus venosus and the presence of left lateral segment portal veins above the diaphragm are the most reliable indicators of liver herniation into the left chest [10]. For right-sided defects, the presence of the gallbladder above the level of the diaphragm can confirm the location of the liver [2].

The lung-to-head ratio (LHR) is another important prognostic indicator. LHR was initially developed for left sided CDH and has been extrapolated to right sided defects [11]. It is obtained by measuring the contralateral lung area at the level of the four-chamber view of the heart and dividing by the head circumference. In multiple studies, an LHR  $<0.6$  was associated with 100% mortality, while an LHR  $>1.35$  was associated with 100% survival [12-15]. When measured correctly, the LHR can be invaluable; however, reproducibility has limited its application. In fact, there are now three different standardized methods for obtaining the LHR which have different survival outcomes [2]. These include the trace method, the Anteroposterior method, and the longest dimension method. A recent study by the North American Fetal Therapy Network (NAFTNet) members examined and validated these three methods and has demonstrated that the trace method is the most accurate and objective [16]. Regardless, the LHR (or variants of the LHR) has been widely accepted. It is important to note that although LHR is also used in right sided defects, it is less prognostic [11, 17].

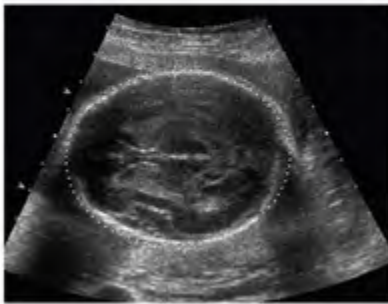Another factor affecting LHR is the gestational age of the fetus. The fetal lung and head grow at different rates, especially up to 32 weeks gestation when lung growth begins to level off relative to the head circumference [9]. This prompted investigators to propose the observed-to-expected ratio for LHR (o/e LHR) based on what the mean expected LHR would be for a specific gestational age in fetuses not affected by CDH [18, 19]. As lung growth plateaus, there is a decrease in the o/e LHR. For example, an LHR of 1.0 correlates with an o/e LHR of 32% at 23 weeks gestation, and an o/e LHR of 23% at 33 weeks gestation for a left-sided defect [20]. In the original description of the o/e LHR for left-sided defects, o/e LHR of  $<25\%$  was associated with an 18% survival; o/e LHR of 26-45% was associated with 66% survival, and o/e LHR of  $>45\%$  was associated with 89% survival [18, 21].

The perinatology.com link for calculating LHR:

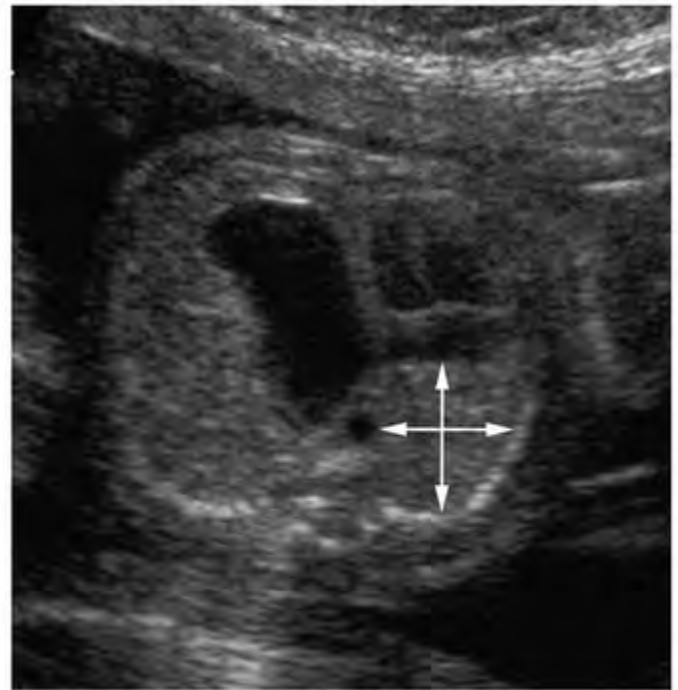
<http://perinatology.com/calculators/LHR.htm>



$$\text{LHR} = \frac{A \times B \text{ (mm)}}{\text{HC (mm)}}$$



A Head Circumference



B

**Lung-to-Head Ratio (LHR) in a fetus with congenital diaphragmatic hernia.** The measurement of the right lung is done in a transverse axial plane of section of the fetal thorax at the level of the four-chamber view of the fetal heart with a single rib visualized on each side. The measurements are made in millimeters and are measured from the thoracic aorta to the lateral inner chest wall (A) and in the plane perpendicular to the first from the outer wall of the atrium to the inner aspect of the posterior chest wall (B). These two measurements are then multiplied by one another and divided by the measurement of the head circumference.

*(Sonographic images courtesy of Roy A. Filly, MD, San Francisco, CA. Illustration courtesy of James A Cooper, MD, San Diego, CA.)*

### *Fetal Magnetic Resonance Imaging*

Fetal magnetic resonance imaging (fMRI) is an emerging imaging modality in the work-up of specific prenatally diagnosed congenital anomalies including CDH where it has primarily been studied in measuring lung volumes for antenatal prognostication. The most important measurement obtained by MRI is the lung volume which is expressed as percent predicted lung volume (PPLV), observed-to-expected fetal lung volume (o/e FLV), and observed-to-expected total fetal lung volume (o/e TFLV) at different centers [22-25]. The PPLV calculation is made by subtracting the mediastinal volume from the thoracic volume to determine the expected lung volume. The actual lung volume is then measured and divided by the expected lung volume to create a percentage [22]. Observed-to-expected FLV and TFLV is calculated based on measuring the actual lung volume of both the right and left lung and dividing the total over the expected lung volume for gestational age [23, 25].

Exactly how the lung volumes should be interpreted is not agreed upon. In one study, PPLV of 15% appeared to be the determinant of survival, where those with a PPLV >20% had 100% survival, whereas a PPLV of <15% was associated with only 40% survival [26]. In another study, the cutoff appeared to be 25% where PPLV <25% was associated with 13% survival, and a PPLV >35% was associated with 83% survival [23]. Others have reported that PPLV is inferior to LHR in predicting volumes [2]. Furthermore, LHR can be obtained by US and does not require a fetal MRI, which is not a routine part of the workup for CDH at all fetal treatment centers [13]. A recent study showed that PPLV decreases throughout gestation and a PPLV <15% initially or a PPLV that dropped to <15% with later gestation are associated with higher ECMO use and higher risk of death [27]. Other groups have looked at the raw fetal lung volume (FLV) as a prognostic indicator [28, 29]. In a series of FLV obtained via MRI at 34-35 weeks gestation, the investigators reported that survivors had a mean FLV of 35ml, those requiring ECMO had a mean FLV of 18ml, and non-survivors had a mean FLV of 9ml [29]. A recent systematic review showed that o/e TFLV could be used to categorize fetuses and predict survival: severe <25% with 0-25% survival, moderate 25-35% with 25-69% survival, and mild >35% with 75-89% survival. This study found that o/e TFLV was superior to US o/e LHR but the difference disappeared when measuring o/e LHR using the tracing method [24].

It has also been reported that the presence of liver-up on MRI, as well as the percentage of herniated liver, were prognostic. Liver-up is widely accepted as a poor prognostic indicator. In the series by Victoria, et al., liver-up was associated with 45% survival, whereas liver-down was associated with 94% survival [23]. Again, this can also be determined by US and does not necessitate a fetal MRI; however this group also looked at herniated liver volumes as determined by fetal MRI and found that survivors had a mean 17% of liver herniated compared to non-survivors who had a mean 28% liver herniated ( $p=0.004$ ) [23]. Additionally, Lazar et al. found that liver herniation greater than 21% was associated with mortality with an 87% accuracy rate ( $p<0.001$ ) and if the liver/thoracic volume ratio was greater than 14% it was associated with mortality with an accuracy of 85% ( $p<0.001$ ) [30].

Some centers also use fetal MRI to predict postnatal pulmonary hypertension. In 2010, one group reported on the importance of calculating a prenatal pulmonary hypertension index (PPHI) and modified McGoon index (MGI) [31]. By calculating diameters of the right pulmonary artery, left pulmonary artery (LPA<sub>d</sub>), aorta, and the vermis of the cerebellum on fetal MRI, the values for PPHI and MGI can be calculated by the following equations:

$$\text{PPHI} = (\text{LPA}_d / \text{length of vermis of cerebellum}) \times 10$$

$$\text{MGI} = (\text{diameter of right pulmonary artery} + \text{LPA}_d) / \text{diameter of aorta at level of diaphragm}$$

In this study, these were shown to better predict postnatal pulmonary hypertension in isolated left CDH than LHR, TLV, or PPLV [31]. The study showed that MGI <0.88 and PPHI <1.54 were predictive of systemic or suprasystemic pulmonary hypertension at 3 weeks by echocardiogram (percent correctly predicted of 89.5% for MGI and 73.7% for PPHI) [31].

### *Imaging for Associated Anomalies*

It is important that an assessment be made to determine if there are any associated anomalies, as these have a significant, negative impact on survival. In fact, 95% of stillborns with CDH have an associated anomaly [32]. These anomalies can include congenital heart disease, genitourinary abnormalities, intestinal atresia, bronchopulmonary sequestrations and neurologic defects – most of which can be detected through prenatal US [2]. Further delineation of suspected anomalies may be better assessed by fetal echocardiogram and fetal MRI, especially if this information would impact the management of the pregnancy.

Amniocentesis should be offered for karyotyping, as well as comparative genomic hybridization microarray, to identify chromosomal abnormalities. This information may be helpful for families making decisions regarding the pregnancy and postnatal care. Up to 20% will have a chromosomal abnormality such as trisomy 21, trisomy 18, or trisomy 13 [2]. CDH can also occur in association with multiple syndromes including Beckwith-Wiedemann, Fryns, and Pierre Robin [33-35]. Lastly, since most fetal interventions are investigational, normal chromosomal studies are necessary for inclusion and suspected syndromes are listed as exclusion criteria.

### **Fetal Interventions**

Fetal interventions are not to be taken lightly. Any fetal intervention carries a risk to both the fetus and a healthy mother. In fact, something as routine as an amniocentesis carries a 0.5-1.4% risk of fetal loss [36]. Fetal interventions are associated with fetal demise, preterm labor, the risk of premature rupture of membranes, chorionic membrane separation, chorioamnionitis, and bleeding [37, 38].

### *Fetal Interventions (History)*

In 1990, Dr. Michael Harrison and his team at UCSF published the first successful open fetal CDH repair[39]. This was followed by a prospective trial comparing open fetal repair (n=4) to postnatal repair (n=7) in pregnancies referred to UCSF at <30 weeks gestation that were

complicated by an isolated left-sided CDH with significant volume displacement of the ipsilateral lung and an intrathoracic stomach. There was no difference in survival and increased prematurity with open fetal repair [40]. Over this same time period, as laparoscopic and video-assisted surgery became more prevalent, fetoscopic surgery emerged as an alternative to open surgery with decreased maternal morbidity. In a review of 187 women who underwent intrauterine fetal intervention, women that underwent fetoscopic surgery compared to open fetal surgery had significantly decreased rates of cesarean birth, treatment in an intensive care unit, prolonged hospitalizations and blood transfusions [41].

Open fetal repair has since been abandoned in favor of tracheal occlusion which, initially was done using tracheal clips during open hysterotomy, but it is now completed fetoscopically [42, 43]. When the fetal trachea is occluded, fluid normally made by the fetal lung parenchyma builds up and leads to pulmonary hyperplasia [44]. This hyperplasia can be so dramatic that it causes eversion of the diaphragms. Since pulmonary hypoplasia is what contributes to morbidity and mortality associated with the CDH, this physiologic process was applied to fetal lambs with CDH [45, 46]. The results were favorable, so clinicians have targeted fetoscopic tracheal occlusion (FETO) as a potential antenatal intervention for CDH patients with an unfavorable diagnosis.

Given these promising findings, multiple groups have studied fetal intervention for pregnancies complicated by severe CDH. Initial studies in the United States, Europe, and South America have mixed results with fetoscopic tracheal occlusion (FETO) [20, 47, 48]. This has led to a consortium of centers that are involved in a randomized controlled trial.

#### *Fetoscopic Tracheal Occlusion (FETO) Consortium and Current Fetal Intervention Options*

Currently, data is limited and there is insufficient evidence to recommend in utero fetal tracheal occlusion for fetuses with CDH as the standard of care [49]. To this end, multiple institutions within the United States, South America and Europe are continuing to examine the effects of in utero fetal tracheal occlusion on overall long term survival and neonatal outcomes in clinical trials. The largest trial underway at this time is the Tracheal Occlusion To Accelerate Lung growth (TOTAL) trial that is an international, multi-center, randomized trial of FETO vs expectant postnatal management [50]. A list of US centers offering fetoscopic tracheal occlusion (FETO) can be viewed at [ClinicalTrials.gov](http://ClinicalTrials.gov).

#### *EXIT to ECMO*

In the absence of tracheal occlusion, some investigators have proposed that EXIT-to-ECMO may be a viable alternative to improve outcomes for unfavorable CDH in an effort to eliminate life threatening hypoxia, instability, or cardiac arrest between the time of birth and ECMO cannulation. The exact criteria for EXIT-to-ECMO remain uncertain. One group published their results from 14 cases using an LHR <1.4 and PPLV <15%. Each patient underwent an EXIT procedure after 36 weeks. An airway was established and a ventilation trial was performed. Eleven patients failed the trial, were cannulated, and then delivered. Three patients passed the

trial of which two eventually required ECMO after delivery. Overall survival was 64%[51]; however this same group followed up their experience and found no survival benefit for EXIT-to-ECMO (33% survival) when compared to those CDH patients requiring ECMO but not undergoing an EXIT procedure (50% survival)[52]. Currently, there does not appear to be a convincing role for EXIT-to-ECMO.

### **Outcomes**

The vast majority of prenatal evaluations will not be candidates for a fetal intervention; therefore families will expect counseling on what to anticipate during the neonatal period and beyond. Clinicians should be prepared to have an in-depth discussion with families during prenatal consultation that encompasses worst- and best-case scenarios, operative timing and types of repair, ECMO, and long-term outcomes. The immediate postnatal management for CDH is beyond the scope of this text; however, long-term outcomes are reviewed in this section.

Survival has been the primary outcome analyzed repeatedly to determine the best strategies for managing CDH; however, CDH covers a broad-spectrum of severity, and it can be difficult to predict which end of the spectrum each case will fall. Due to this broad range of severity, a risk assessment tool was developed by the Congenital Diaphragmatic Hernia Study Group based on multi-institutional data to risk stratify neonatal CDH and predict mortality as well as compare outcome data from different centers [53]. Using this equation (probability of survival =  $1 - (1 + e^{-x})$  where  $-x = -5.0240 + 0.9165(\text{birth weight in kilograms}) + 0.4512(\text{APGAR score at 5 minutes})$ ), centers have examined their own outcomes compared to expected and have found survival rates for CDH neonates to be 60-93% [54-57]. To further compound on this data, the Canadian Neonatal Network, upon review of their registry found that 83% of neonates with CDH survived to discharge. And, when this was broken down to high vs. low volume centers, CDH survival was significantly greater at high volume centers (90% vs. 77% respectively;  $p < 0.01$ ) [58].

When looking back at the last several decades, this survival rate has dramatically improved with both improvements in healthcare and evolving treatment strategies. In a review of 27 years of experience with CDH treatment, one institution found significant improvements in their survival rate over time. In era 1 (1970-1983), survival was 42%, in era 2 (1984-1988) survival was 58% and in era 3 (1989-1997) survival was found to be 79% ( $P < 0.02$  era 3 vs. both era 1 and 2) [59]. This dramatic improvement in survival over the last several decades should only continue to improve as we advance in surgical technology and post-operative management.

Survivors are still at risk for other long-term problems. The most common problems are respiratory, neurologic, and GI related. Prolonged ventilator dependence can lead to bronchopulmonary dysplasia in 41% and there is a higher rate of reactive airway disease in children with a history of CDH [60, 61]. Also, when CDH survivors underwent assessment of pulmonary function and exercise capacity (mean age  $11.9 \pm 3.5$  years), they were found to have significantly lower forced expiratory volume in 1 second (FEV1), forced vital capacity (FVC), and



FEV1/FVC when compared to healthy controls while exercise capacity was normal in those that were tested [62].

Up to 50% have some degree of neurologic sequelae which is independent of the need for ECMO. Sensorineural hearing loss can manifest later in life and requires routine follow-up. Children with CDH can be affected by cerebral palsy, delay in speech and verbal skills, vision loss, and seizure disorders [63].

Gastroesophageal reflux can be a problem in up to 60% of which 10-15% will require an anti-reflux procedure [64, 65]. Nutrition can be a problem for these children who can have respiratory symptoms during feeding contributing to poor growth and failure to thrive with over 50% below the 25<sup>th</sup> percentile for weight at one year of age [66]. Fortunately, this delay in growth appears to normalize by two years, but 1/3 will require a gastrostomy tube [67, 68]. Growth can also be affected by chest wall deformities in 20% who will develop a pectus excavatum defect and 10% that will develop scoliosis [68].

Recurrence rates are high after repair of the defect and overall are reported between 5-20%; however, if a prosthetic patch was required, then recurrence is as high as 50% [69] [70]. The group in Salt Lake City has published favorable rates using an internal oblique muscle flap for large defects with a recurrence rate of 4% at median follow up of four years [71]. Lastly, small bowel obstruction has been reported after CDH repair and is reported more commonly in those patients who require patch rather than primary repair [72].

### **Conclusions**

Congenital diaphragmatic hernia is a frequently encountered congenital anomaly that spans a wide spectrum of severity. Improved prenatal diagnosis has led to the detailing of several prognostic parameters that are critical (albeit imperfect) in counseling families and determining candidates for fetal intervention. Most pregnancies will not be a candidate for fetal intervention. The pediatric surgeon should still be able to provide valuable prognostic information that will guide families as they decide what level of care they want for their baby, who may ultimately benefit from a delivery plan that ensures the availability of appropriate resources.

### **Level of Evidence**

Grade C, Level 4 (Case series and extrapolation from small case-control series)

## References

- [1] Chinn DH, Filly RA, Callen PW, Nakayama DK, Harrison MR. Congenital diaphragmatic hernia diagnosed prenatally by ultrasound. *Radiology* 1983;148(1):119-23.
- [2] Bianchi DW CT, D'Alton ME, Malone FD, eds. *Fetology*. 2nd Edition ed. New York, NY: McGraw-Hill; 2010.
- [3] Harrison MR, Bjordal RI, Langmark F, Knutrud O. Congenital diaphragmatic hernia: the hidden mortality. *Journal of pediatric surgery* 1978;13(3):227-30.
- [4] Skari H, Bjornland K, Haugen G, Egeland T, Emblem R. Congenital diaphragmatic hernia: a meta-analysis of mortality factors. *Journal of pediatric surgery* 2000;35(8):1187-97.
- [5] Nakayama DK, Harrison MR, Chinn DH, Callen PW, Filly RA, Golbus MS, et al. Prenatal diagnosis and natural history of the fetus with a congenital diaphragmatic hernia: initial clinical experience. *Journal of pediatric surgery* 1985;20(2):118-24.
- [6] Adzick NS, Vacanti JP, Lillehei CW, O'Rourke PP, Crone RK, Wilson JM. Fetal diaphragmatic hernia: ultrasound diagnosis and clinical outcome in 38 cases. *Journal of pediatric surgery* 1989;24(7):654-7; discussion 7-8.
- [7] Harrison MR GM, Filly RA, eds. *The Unborn Patient: Prenatal Diagnosis and Treatment*. 2nd Edition ed. Philadelphia, PA: WB Saunders; 1991.
- [8] Harrison MR, Langer JC, Adzick NS, Golbus MS, Filly RA, Anderson RL, et al. Correction of congenital diaphragmatic hernia in utero, V. Initial clinical experience. *Journal of pediatric surgery* 1990;25(1):47-55; discussion 6-7.
- [9] Deprest JA, Hyett JA, Flake AW, Nicolaides K, Gratacos E. Current controversies in prenatal diagnosis 4: Should fetal surgery be done in all cases of severe diaphragmatic hernia? *Prenatal diagnosis* 2009;29(1):15-9.
- [10] Bootstaylor BS, Filly RA, Harrison MR, Adzick NS. Prenatal sonographic predictors of liver herniation in congenital diaphragmatic hernia. *Journal of ultrasound in medicine : official journal of the American Institute of Ultrasound in Medicine* 1995;14(7):515-20.
- [11] Victoria T, Danzer E, Oliver ER, Edgar JC, Iyob S, Partridge EA, et al. Right Congenital Diaphragmatic Hernias: Is There a Correlation between Prenatal Lung Volume and Postnatal Survival, as in Isolated Left Diaphragmatic Hernias? *Fetal diagnosis and therapy* 2018;43(1):12-8.
- [12] Metkus AP, Filly RA, Stringer MD, Harrison MR, Adzick NS. Sonographic predictors of survival in fetal diaphragmatic hernia. *Journal of pediatric surgery* 1996;31(1):148-51; discussion 51-2.
- [13] Keller RL, Glidden DV, Paek BW, Goldstein RB, Feldstein VA, Callen PW, et al. The lung-to-head ratio and fetoscopic temporary tracheal occlusion: prediction of survival in severe left congenital diaphragmatic hernia. *Ultrasound in obstetrics & gynecology : the official journal of the International Society of Ultrasound in Obstetrics and Gynecology* 2003;21(3):244-9.
- [14] Lipshutz GS, Albanese CT, Feldstein VA, Jennings RW, Housley HT, Beech R, et al. Prospective analysis of lung-to-head ratio predicts survival for patients with prenatally diagnosed congenital diaphragmatic hernia. *Journal of pediatric surgery* 1997;32(11):1634-6.
- [15] Yang SH, Nobuhara KK, Keller RL, Ball RH, Goldstein RB, Feldstein VA, et al. Reliability of the lung-to-head ratio as a predictor of outcome in fetuses with isolated left congenital diaphragmatic hernia at gestation outside 24-26 weeks. *American journal of obstetrics and gynecology* 2007;197(1):30.e1-7.
- [16] Abbasi N, Ryan G, Johnson A, Sanz Cortes M, Sangi-Haghpeykar H, Ye XY, et al. Reproducibility of fetal lung-to-head ratio in left diaphragmatic hernia across the North American Fetal Therapy Network (NAFTNet). *Prenatal diagnosis* 2019.

- [17] Sperling JD, Sparks TN, Berger VK, Farrell JA, Gosnell K, Keller RL, et al. Prenatal Diagnosis of Congenital Diaphragmatic Hernia: Does Laterality Predict Perinatal Outcomes? *American journal of perinatology* 2018.
- [18] Jani J, Nicolaides KH, Keller RL, Benachi A, Peralta CF, Favre R, et al. Observed to expected lung area to head circumference ratio in the prediction of survival in fetuses with isolated diaphragmatic hernia. *Ultrasound in obstetrics & gynecology : the official journal of the International Society of Ultrasound in Obstetrics and Gynecology* 2007;30(1):67-71.
- [19] Cruz-Martinez R, Castanon M, Moreno-Alvarez O, Acosta-Rojas R, Martinez JM, Gratacos E. Usefulness of lung-to-head ratio and intrapulmonary arterial Doppler in predicting neonatal morbidity in fetuses with congenital diaphragmatic hernia treated with fetoscopic tracheal occlusion. *Ultrasound in obstetrics & gynecology : the official journal of the International Society of Ultrasound in Obstetrics and Gynecology* 2013;41(1):59-65.
- [20] Jani JC, Nicolaides KH, Gratacos E, Valencia CM, Done E, Martinez JM, et al. Severe diaphragmatic hernia treated by fetal endoscopic tracheal occlusion. *Ultrasound in obstetrics & gynecology : the official journal of the International Society of Ultrasound in Obstetrics and Gynecology* 2009;34(3):304-10.
- [21] Jani JC, Benachi A, Nicolaides KH, Allegaert K, Gratacos E, Mazkereth R, et al. Prenatal prediction of neonatal morbidity in survivors with congenital diaphragmatic hernia: a multicenter study. *Ultrasound in obstetrics & gynecology : the official journal of the International Society of Ultrasound in Obstetrics and Gynecology* 2009;33(1):64-9.
- [22] Mahieu-Caputo D, Sonigo P, Dommergues M, Fournet JC, Thalabard JC, Abarca C, et al. Fetal lung volume measurement by magnetic resonance imaging in congenital diaphragmatic hernia. *BJOG : an international journal of obstetrics and gynaecology* 2001;108(8):863-8.
- [23] Victoria T, Bebbington MW, Danzer E, Flake AW, Johnson MP, Dinan D, et al. Use of magnetic resonance imaging in prenatal prognosis of the fetus with isolated left congenital diaphragmatic hernia. *Prenatal diagnosis* 2012;32(8):715-23.
- [24] Oluyomi-Obi T, Van Mieghem T, Ryan G. Fetal imaging and therapy for CDH-Current status. *Semin Pediatr Surg* 2017;26(3):140-6.
- [25] Cannie M, Jani J, Meersschaert J, Allegaert K, Done E, Marchal G, et al. Prenatal prediction of survival in isolated diaphragmatic hernia using observed to expected total fetal lung volume determined by magnetic resonance imaging based on either gestational age or fetal body volume. *Ultrasound in obstetrics & gynecology : the official journal of the International Society of Ultrasound in Obstetrics and Gynecology* 2008;32(5):633-9.
- [26] Barnewolt CE, Kunisaki SM, Fauza DO, Nemes LP, Estroff JA, Jennings RW. Percent predicted lung volumes as measured on fetal magnetic resonance imaging: a useful biometric parameter for risk stratification in congenital diaphragmatic hernia. *Journal of pediatric surgery* 2007;42(1):193-7.
- [27] Shieh HF, Barnewolt CE, Wilson JM, Zurakowski D, Connolly SA, Estroff JA, et al. Percent predicted lung volume changes on fetal magnetic resonance imaging throughout gestation in congenital diaphragmatic hernia. *Journal of pediatric surgery* 2017;52(6):933-7.
- [28] Hubbard AM, Adzick NS, Crombleholme TM, Haselgrove JC. Left-sided congenital diaphragmatic hernia: value of prenatal MR imaging in preparation for fetal surgery. *Radiology* 1997;203(3):636-40.
- [29] Kilian AK, Busing KA, Schaible T, Neff KW. [Fetal magnetic resonance imaging. Diagnostics in congenital diaphragmatic hernia]. *Der Radiologe* 2006;46(2):128-32.
- [30] Lazar DA, Ruano R, Cass DL, Moise KJ, Jr., Johnson A, Lee TC, et al. Defining "liver-up": does the volume of liver herniation predict outcome for fetuses with isolated left-sided congenital diaphragmatic hernia? *Journal of pediatric surgery* 2012;47(6):1058-62.

- [31] Vuletin JF, Lim FY, Cnota J, Kline-Fath B, Salisbury S, Haberman B, et al. Prenatal pulmonary hypertension index: novel prenatal predictor of severe postnatal pulmonary artery hypertension in antenatally diagnosed congenital diaphragmatic hernia. *Journal of pediatric surgery* 2010;45(4):703-8.
- [32] Puri P, Gorman F. Lethal nonpulmonary anomalies associated with congenital diaphragmatic hernia: implications for early intrauterine surgery. *Journal of pediatric surgery* 1984;19(1):29-32.
- [33] Neville HL, Jaksic T, Wilson JM, Lally PA, Hardin WD, Jr., Hirschl RB, et al. Fryns syndrome in children with congenital diaphragmatic hernia. *Journal of pediatric surgery* 2002;37(12):1685-7.
- [34] Cunniff C, Jones KL, Jones MC. Patterns of malformation in children with congenital diaphragmatic defects. *J Pediatr* 1990;116(2):258-61.
- [35] Witters I, Legius E, Moerman P, Deprest J, Van Schoubroeck D, Timmerman D, et al. Associated malformations and chromosomal anomalies in 42 cases of prenatally diagnosed diaphragmatic hernia. *Am J Med Genet* 2001;103(4):278-82.
- [36] Tabor A, Vestergaard CH, Lidegaard O. Fetal loss rate after chorionic villus sampling and amniocentesis: an 11-year national registry study. *Ultrasound in obstetrics & gynecology : the official journal of the International Society of Ultrasound in Obstetrics and Gynecology* 2009;34(1):19-24.
- [37] Longaker MT, Golbus MS, Filly RA, Rosen MA, Chang SW, Harrison MR. Maternal outcome after open fetal surgery. A review of the first 17 human cases. *JAMA* 1991;265(6):737-41.
- [38] Chang J, Tracy TF, Jr., Carr SR, Sorrells DL, Jr., Luks FI. Port insertion and removal techniques to minimize premature rupture of the membranes in endoscopic fetal surgery. *Journal of pediatric surgery* 2006;41(5):905-9.
- [39] Harrison MR, Adzick NS, Longaker MT, Goldberg JD, Rosen MA, Filly RA, et al. Successful repair in utero of a fetal diaphragmatic hernia after removal of herniated viscera from the left thorax. *The New England journal of medicine* 1990;322(22):1582-4.
- [40] Harrison MR, Adzick NS, Bullard KM, Farrell JA, Howell LJ, Rosen MA, et al. Correction of congenital diaphragmatic hernia in utero VII: a prospective trial. *Journal of pediatric surgery* 1997;32(11):1637-42.
- [41] Golombeck K, Ball RH, Lee H, Farrell JA, Farmer DL, Jacobs VR, et al. Maternal morbidity after maternal-fetal surgery. *American journal of obstetrics and gynecology* 2006;194(3):834-9.
- [42] Harrison MR, Adzick NS, Flake AW, VanderWall KJ, Bealer JF, Howell LJ, et al. Correction of congenital diaphragmatic hernia in utero VIII: Response of the hypoplastic lung to tracheal occlusion. *Journal of pediatric surgery* 1996;31(10):1339-48.
- [43] Harrison MR, Mychaliska GB, Albanese CT, Jennings RW, Farrell JA, Hawgood S, et al. Correction of congenital diaphragmatic hernia in utero IX: fetuses with poor prognosis (liver herniation and low lung-to-head ratio) can be saved by fetoscopic temporary tracheal occlusion. *Journal of pediatric surgery* 1998;33(7):1017-22; discussion 22-3.
- [44] Carmel JA, Friedman F, Adams FH. FETAL TRACHEAL LIGATION AND LUNG DEVELOPMENT. *American journal of diseases of children (1960)* 1965;109:452-6.
- [45] Hedrick MH, Estes JM, Sullivan KM, Bealer JF, Kitterman JA, Flake AW, et al. Plug the lung until it grows (PLUG): a new method to treat congenital diaphragmatic hernia in utero. *Journal of pediatric surgery* 1994;29(5):612-7.
- [46] Beierle EA, Langham MR, Jr., Cassin S. In utero lung growth of fetal sheep with diaphragmatic hernia and tracheal stenosis. *Journal of pediatric surgery* 1996;31(1):141-6; discussion 6-7.
- [47] Harrison MR, Keller RL, Hawgood SB, Kitterman JA, Sandberg PL, Farmer DL, et al. A randomized trial of fetal endoscopic tracheal occlusion for severe fetal congenital diaphragmatic hernia. *The New England journal of medicine* 2003;349(20):1916-24.

- [48] Ruano R, Yoshisaki CT, da Silva MM, Ceccon ME, Grasi MS, Tannuri U, et al. A randomized controlled trial of fetal endoscopic tracheal occlusion versus postnatal management of severe isolated congenital diaphragmatic hernia. *Ultrasound in obstetrics & gynecology : the official journal of the International Society of Ultrasound in Obstetrics and Gynecology* 2012;39(1):20-7.
- [49] Araujo Junior E, Tonni G, Martins WP, Ruano R. Procedure-Related Complications and Survival Following Fetoscopic Endotracheal Occlusion (FETO) for Severe Congenital Diaphragmatic Hernia: Systematic Review and Meta-Analysis in the FETO Era. *European journal of pediatric surgery : official journal of Austrian Association of Pediatric Surgery [et al] = Zeitschrift fur Kinderchirurgie* 2017;27(4):297-305.
- [50] Deprest J, Brady P, Nicolaidis K, Benachi A, Berg C, Vermeesch J, et al. Prenatal management of the fetus with isolated congenital diaphragmatic hernia in the era of the TOTAL trial. *Seminars in fetal & neonatal medicine* 2014;19(6):338-48.
- [51] Kunisaki SM, Barnewolt CE, Estroff JA, Myers LB, Fauza DO, Wilkins-Haug LE, et al. Ex utero intrapartum treatment with extracorporeal membrane oxygenation for severe congenital diaphragmatic hernia. *Journal of pediatric surgery* 2007;42(1):98-104; discussion -6.
- [52] Stoffan AP, Wilson JM, Jennings RW, Wilkins-Haug LE, Buchmiller TL. Does the ex utero intrapartum treatment to extracorporeal membrane oxygenation procedure change outcomes for high-risk patients with congenital diaphragmatic hernia? *Journal of pediatric surgery* 2012;47(6):1053-7.
- [53] Congenital Diaphragmatic Hernia Study G. Estimating disease severity of congenital diaphragmatic hernia in the first 5 minutes of life. *Journal of pediatric surgery* 2001;36(1):141-5.
- [54] Downard CD, Jaksic T, Garza JJ, Dzakovic A, Nemes L, Jennings RW, et al. Analysis of an improved survival rate for congenital diaphragmatic hernia. *Journal of pediatric surgery* 2003;38(5):729-32.
- [55] Migliazza L, Bellan C, Alberti D, Auriemma A, Burgio G, Locatelli G, et al. Retrospective study of 111 cases of congenital diaphragmatic hernia treated with early high-frequency oscillatory ventilation and presurgical stabilization. *Journal of pediatric surgery* 2007;42(9):1526-32.
- [56] Hedrick HL, Crombleholme TM, Flake AW, Nance ML, von Allmen D, Howell LJ, et al. Right congenital diaphragmatic hernia: Prenatal assessment and outcome. *Journal of pediatric surgery* 2004;39(3):319-23; discussion -23.
- [57] Steinhorn RH, Kriesmer PJ, Green TP, McKay CJ, Payne NR. Congenital diaphragmatic hernia in Minnesota. Impact of antenatal diagnosis on survival. *Arch Pediatr Adolesc Med* 1994;148(6):626-31.
- [58] Javid PJ, Jaksic T, Skarsgard ED, Lee S, Canadian Neonatal N. Survival rate in congenital diaphragmatic hernia: the experience of the Canadian Neonatal Network. *Journal of pediatric surgery* 2004;39(5):657-60.
- [59] Weber TR, Kountzman B, Dillon PA, Silen ML. Improved survival in congenital diaphragmatic hernia with evolving therapeutic strategies. *Arch Surg* 1998;133(5):498-502; discussion -3.
- [60] van den Hout L, Reiss I, Felix JF, Hop WC, Lally PA, Lally KP, et al. Risk factors for chronic lung disease and mortality in newborns with congenital diaphragmatic hernia. *Neonatology* 2010;98(4):370-80.
- [61] Rocha G, Azevedo I, Pinto JC, Guimaraes H. Follow-up of the survivors of congenital diaphragmatic hernia. *Early Hum Dev* 2012;88(4):255-8.
- [62] Peetsold MG, Heij HA, Nagelkerke AF, Ijsselstijn H, Tibboel D, Quanjer PH, et al. Pulmonary function and exercise capacity in survivors of congenital diaphragmatic hernia. *Eur Respir J* 2009;34(5):1140-7.
- [63] Lund DP, Mitchell J, Kharasch V, Quigley S, Kuehn M, Wilson JM. Congenital diaphragmatic hernia: the hidden morbidity. *Journal of pediatric surgery* 1994;29(2):258-62; discussion 62-4.

- [64] Koot VC, Bergmeijer JH, Bos AP, Molenaar JC. Incidence and management of gastroesophageal reflux after repair of congenital diaphragmatic hernia. *Journal of pediatric surgery* 1993;28(1):48-52.
- [65] Kieffer J, Sapin E, Berg A, Beaudoin S, Bargo F, Helardot PG. Gastroesophageal reflux after repair of congenital diaphragmatic hernia. *Journal of pediatric surgery* 1995;30(9):1330-3.
- [66] Muratore CS, Utter S, Jaksic T, Lund DP, Wilson JM. Nutritional morbidity in survivors of congenital diaphragmatic hernia. *Journal of pediatric surgery* 2001;36(8):1171-6.
- [67] Rudra S, Adibe OO, Malcolm WF, Smith PB, Cotten CM, Greenberg RG. Gastrostomy tube placement in infants with congenital diaphragmatic hernia: Frequency, predictors, and growth outcomes. *Early Hum Dev* 2016;103:97-100.
- [68] Nobuhara KK, Lund DP, Mitchell J, Kharasch V, Wilson JM. Long-term outlook for survivors of congenital diaphragmatic hernia. *Clinics in perinatology* 1996;23(4):873-87.
- [69] Grethel EJ, Cortes RA, Wagner AJ, Clifton MS, Lee H, Farmer DL, et al. Prosthetic patches for congenital diaphragmatic hernia repair: Surgisis vs Gore-Tex. *Journal of pediatric surgery* 2006;41(1):29-33; discussion 29-33.
- [70] Moss RL, Chen CM, Harrison MR. Prosthetic patch durability in congenital diaphragmatic hernia: a long-term follow-up study. *Journal of pediatric surgery* 2001;36(1):152-4.
- [71] Barnhart DC, Jacques E, Scaife ER, Yoder BA, Meyers RL, Harman A, et al. Split abdominal wall muscle flap repair vs patch repair of large congenital diaphragmatic hernias. *Journal of pediatric surgery* 2012;47(1):81-6.
- [72] St Peter SD, Valusek PA, Tsao K, Holcomb GW, 3rd, Ostlie DJ, Snyder CL. Abdominal complications related to type of repair for congenital diaphragmatic hernia. *J Surg Res* 2007;140(2):234-6.

## Sacrococcygeal Tumors

Erin E. Perrone and Corey W. Iqbal

### Introduction

Sacrococcygeal tumor (SCT) is a rare neoplasm that is being diagnosed with increasing frequency *in utero*. Fetuses with SCT are susceptible to intra-uterine fetal demise (IUFD). These tumors arise from the coccyx, are derived from the 3 embryonic layers, and are generally benign in fetal and early neonatal life[1, 2]. However, SCTs can grow to a tremendous size in relation to the fetus and can cause high-output cardiac failure and non-immune hydrops through vascular shunting. Rarely, tumors can hemorrhage internally or externally, resulting in fetal anemia, hypovolemia and IUFD[3-5]. Other potential problems for a fetus with a large SCT are dystocia and pre-term labor. Delivery can be particularly difficult when the diagnosis has not been made prenatally. A traumatic delivery may result in tumor rupture and/or hemorrhage. Most clinicians favor cesarean delivery for fetuses with large SCTs[2]. Thus, prenatal diagnosis and careful obstetrical planning are critical in the appropriate management of such pregnancies.

### Tumor Volume to Fetal Weight Ratio

The tumor volume to fetal weight ratio (TFR) is an important prognostic indicator for SCT[6]. Tumor volume is calculated using the greatest length, width and height of the tumor as measured by US or MRI; fetal weight is calculated by US using the Hadlock formula. In the initial report from Texas Children's Hospital of 10 fetuses with SCT, a TFR >0.12 was associated with an 80% incidence of hydrops and a 60% mortality rate, whereas a TFR <0.12 was associated with 100% survival[6]. UCSF has also presented their experience in 37 fetuses with SCT and confirmed that a TFR <0.12 was a favorable prognostic finding up to 24 weeks. Between 24-32 weeks, a TFR of <0.11 was associated with more favorable outcomes. In addition, they also found that cystic SCTs had a more favorable prognosis than solid ones[7]. In 2015, a multi-institutional review validated a TFR >0.12 prior to 24 weeks, solid tumor morphology, and presence of fetal hydrops as predictors of poor prognosis[3].

### Vascular Shunting

Large sacrococcygeal tumors may cause high-output cardiac failure and lead to fetal hydrops[8]. A normal combined ventricular output is 550ml/min/kg and values above this are associated with poor outcomes[5]. Fetal surgical resection may be indicated for fetuses with this physiology where the teratoma acts as a large arteriovenous fistula[8].

### Spinal Canal Invasion

Tumor invasion into the spinal canal is a known complicating factor of sacrococcygeal tumors and can be diagnosed prenatally by both ultrasound and fetal MRI[9, 10]. Although this is a rare occurrence, it can have the devastating complication of permanent paraplegia[11]. A recent

case report described a prenatally diagnosed significant spinal canal invasion of a type IV SCT in which early delivery was chosen to avoid any potential for paraplegia. The authors conclude that these cases need to be treated with a multidisciplinary approach and the risks of prematurity need to be weighed against the risks of neurologic complications[12].

### **Referral for Prenatal Therapy**

A fetus with a high risk SCT should be evaluated and monitored closely in an experienced center to determine the need for fetal intervention. SCT fetal interventions to date have included fetal surgery, radiofrequency ablation (RFA) and EXIT-to-resection. Fetal interventions are typically reserved for fetuses <26 weeks gestational age[13]. Outcomes of fetal intervention are mixed, with survival ranging from 38-75%[14, 15]. However, survival in hydroptic SCT patients not undergoing fetal intervention is likely < 10%[14]. For fetuses presenting >27 weeks, the morbidity of fetal intervention must be weighed against the risk of early delivery and postnatal resection[13, 16].

The most common approach for fetal resection of an SCT is a maternal hysterotomy with resection or debulking of the tumor. Typically, only Type 1 or Type II SCTs are amenable to fetal surgery as they have an external component amenable to fetal intervention. A predominantly cystic lesion may be amenable to percutaneous drainage or shunt placement; however, that is usually unnecessary as cystic SCTs carry a more favorable prognosis[17]. Decompression of a large, cystic SCT may be indicated just prior to delivery to prevent dystocia or to facilitate Cesarean delivery[18]. Tumor debulking using percutaneous coagulation techniques such as radio-frequency ablation or laser coagulation to decrease the vascular shunt are minimally invasive alternatives to open resection that have been reported and may warrant further investigation[19]; however, long-term complications noted in the survivors due to injury to adjacent structures demands a better understanding of the application of these techniques for SCTs[20].

### **Level of Evidence**

Grade C, Level 4 (Case series)



## References

- [1] Gross RW, Clatworthy HW, Jr., Meeker IA, Jr. Sacrococcygeal teratomas in infants and children; a report of 40 cases. *Surgery, gynecology & obstetrics* 1951;92(3):341-54.
- [2] Altman RP, Randolph JG, Lilly JR. Sacrococcygeal teratoma: American Academy of Pediatrics Surgical Section Survey-1973. *Journal of pediatric surgery* 1974;9(3):389-98.
- [3] Akinkuotu AC, Coleman A, Shue E, Sheikh F, Hirose S, Lim FY, et al. Predictors of poor prognosis in prenatally diagnosed sacrococcygeal teratoma: A multiinstitutional review. *Journal of pediatric surgery* 2015;50(5):771-4.
- [4] Olutoye OO, Johnson MP, Coleman BG, Crombleholme TM, Adzick NS, Flake AW. Abnormal umbilical cord Doppler sonograms may predict impending demise in fetuses with sacrococcygeal teratoma. A report of two cases. *Fetal diagnosis and therapy* 2004;19(1):35-9.
- [5] Byrne FA, Lee H, Kipps AK, Brook MM, Moon-Grady AJ. Echocardiographic risk stratification of fetuses with sacrococcygeal teratoma and twin-reversed arterial perfusion. *Fetal diagnosis and therapy* 2011;30(4):280-8.
- [6] Rodriguez MA, Cass DL, Lazar DA, Cassady CI, Moise KJ, Johnson A, et al. Tumor volume to fetal weight ratio as an early prognostic classification for fetal sacrococcygeal teratoma. *Journal of pediatric surgery* 2011;46(6):1182-5.
- [7] Shue E, Bolouri M, Jelin EB, Vu L, Bratton B, Cedars E, et al. Tumor metrics and morphology predict poor prognosis in prenatally diagnosed sacrococcygeal teratoma: a 25-year experience at a single institution. *Journal of pediatric surgery* 2013;48(6):1225-31.
- [8] Schmidt KG, Silverman NH, Harison MR, Callen PW. High-output cardiac failure in fetuses with large sacrococcygeal teratoma: diagnosis by echocardiography and Doppler ultrasound. *The Journal of pediatrics* 1989;114(6):1023-8.
- [9] Jelin E, Jelin AC, Lee H. Sacrococcygeal teratoma with spinal canal invasion prenatally diagnosed. *Journal of pediatric surgery* 2009;44(4):E9-11.
- [10] Danzer E, Hubbard AM, Hedrick HL, Johnson MP, Wilson RD, Howell LJ, et al. Diagnosis and characterization of fetal sacrococcygeal teratoma with prenatal MRI. *AJR American journal of roentgenology* 2006;187(4):W350-6.
- [11] Kunisaki SM, Maher CO, Powelson I, Gemmete JJ, Hirschl RB, Mychaliska GB. Benign sacrococcygeal teratoma with spinal canal invasion and paraplegia. *Journal of pediatric surgery* 2011;46(9):e1-4.
- [12] Perrone EE, Jarboe MD, Maher CO, Berman DR, Ladino-Torres M, Kreutzman J, et al. Early Delivery of Sacrococcygeal Teratoma with Intraspinal Extension. *Fetal diagnosis and therapy* 2018;43(1):72-6.
- [13] Ibele A, Flake A, Shaaban A. Survival of a profoundly hydropic fetus with a sacrococcygeal teratoma delivered at 27 weeks of gestation for maternal mirror syndrome. *Journal of pediatric surgery* 2008;43(8):e17-20.
- [14] Hedrick HL, Flake AW, Crombleholme TM, Howell LJ, Johnson MP, Wilson RD, et al. Sacrococcygeal teratoma: prenatal assessment, fetal intervention, and outcome. *Journal of pediatric surgery* 2004;39(3):430-8; discussion -8.
- [15] Adzick NS. Open fetal surgery for life-threatening fetal anomalies. *Seminars in fetal & neonatal medicine* 2010;15(1):1-8.
- [16] Roybal JL, Moldenhauer JS, Khalek N, Bebbington MW, Johnson MP, Hedrick HL, et al. Early delivery as an alternative management strategy for selected high-risk fetal sacrococcygeal teratomas. *Journal of pediatric surgery* 2011;46(7):1325-32.
- [17] Lee MY, Won HS, Hyun MK, Lee HY, Shim JY, Lee PR, et al. Perinatal outcome of sacrococcygeal teratoma. *Prenatal diagnosis* 2011;31(13):1217-21.

- [18] Hirose S, Farmer DL. Fetal surgery for sacrococcygeal teratoma. *Clinics in perinatology* 2003;30(3):493-506.
- [19] Ruano R, Duarte S, Zugaib M. Percutaneous laser ablation of sacrococcygeal teratoma in a hydropic fetus with severe heart failure--too late for a surgical procedure? *Fetal diagnosis and therapy* 2009;25(1):26-30.
- [20] Paek BW, Jennings RW, Harrison MR, Filly RA, Tacy TA, Farmer DL, et al. Radiofrequency ablation of human fetal sacrococcygeal teratoma. *American journal of obstetrics and gynecology* 2001;184(3):503-7.

## Fetal Masses and Neoplasms

Corey W. Iqbal, Abdalla E. Zarroug, David T. Schindel

### Introduction

Ultrasound is paramount in distinguishing the anatomic location of the cyst, as well as characterizing the lesion to facilitate accurate diagnosis. The observation of peristalsis narrows the differential diagnosis of an abdominal cyst to the gastrointestinal tract[1]. A cyst or mass can become problematic if it grows to a size that results in local compression of intra-abdominal structures; specifically the gastrointestinal tract or the urinary tract. Compression that results in a bowel obstruction can lead to polyhydramnios which can result in preterm labor; compression of the urinary system can result in urinary obstruction and renal damage. Although these types of obstruction can be readily relieved through percutaneous cyst aspiration, the rate of recurrence is high[2]. Fortunately, most cysts identified prenatally rarely necessitate a fetal intervention. In fact, the most common indication reported for fetal cyst aspiration has been for diagnostic purposes. This is generally unnecessary as these lesions are rarely life-threatening[3].

### Fetal Ovarian Lesions

Ovarian cysts arise from ovarian follicles, and their growth is believed to be stimulated by fetal, maternal and placental hormones; although once diagnosed, they do not appear to change in size and many spontaneously resolve postnatally[4, 5]. The majority of cysts are unilateral and can be described as either simple or complex. Ovarian torsion has been reported in 40% of prenatally diagnosed ovarian cysts and may present as a complex or heterogenous cyst of the ovary and unilateral or bilateral[6, 7]. A daughter cyst may occasionally be observed and is pathognomonic for a cyst of ovarian origin[7]. Like all other abdominal cysts, ovarian cysts can become problematic if they are large in size. In one series, ovarian cysts >6cm in diameter can be associated with partial small bowel obstruction, polyhydramnios and preterm labor[8]. Multiple reports have investigated percutaneous aspiration of the fetal ovarian cyst citing two benefits: prevention of polyhydramnios and prevention of ovarian torsion[9, 10]. In the most cited series, Crombleholme recommends that a cyst size of >4cm, the presence of a “wandering” mass or rapid growth of the cyst should be indications for aspiration primarily to prevent torsion and loss of the ovary[10]. In the absence of these findings, ovarian cysts can be observed and studied postnatally with ultrasonography, as up to 50% will resolve spontaneously once the neonate is out of the hormonal milieu. Unlike older children, complex cysts in the fetus and newborn are almost never associated with neoplasms and therefore intervention in the fetus or neonate based on malignancy is not warranted even with “complex” cysts. Although usually echo-free, echoes and septations can appear in the setting of torsion that give this “complex” appearance. Cystic masses can be found outside the pelvis

in the abdomen. An appropriate differential includes duplication cysts, mesenteric cysts, omental cysts, lymphangioma, choledochal cysts, meconium peritonitis, ureteral cysts, liver cysts, urachal cyst, hydrometrocolpos and sacrococcygeal teratoma[11]. Polyhydramnios has been reported in association with ovarian masses, and those fetuses should be monitored for pre-term labor, hydrops-fetalis and cardiopulmonary distress immediately after birth. Aspiration of ovarian cysts for polyhydramnios is controversial, but has been performed safely. Aspiration carries with it certain risks as well such as bleeding, intestinal injury, pre-term labor and fetal demise. Some authors have advocated aspiration of “larger” (>4cm) cysts, however, this recommendation is not widely supported. Moreover, cyst recurrence after prenatal aspiration is frequent. Aspiration of the cyst when hydrops-fetalis occurs seems more pragmatic. Overall, no fetal intervention is required for ovarian masses unless hydrops fetalis occurs. Following delivery, postnatal serial ultrasounds should be performed to document initial size, complexity and resolution of asymptomatic cysts. Other investigations may be required if the diagnosis is not clear. An area of controversy regarding the prenatally diagnosed ovarian cysts centers around when and how to intervene after delivery. Some authors have advocated surgical intervention for masses or cysts greater than 6cm, signs of torsion or hemorrhage, presence of calcifications, or lack of resolution[10]. If the diagnosis is unclear, then additional diagnostic procedures are warranted including exploration if needed. Most would agree that evidence suggesting failure of resolution of cysts after 3-4 months of observation, no matter how benign appearing, warrants exploration. The decision to intervene might be considered for masses greater than 5-6cm in neonates based purely on size to prevent torsion[10]. Others have demonstrated that postnatal torsion regardless of cyst size is rare. These authors advocate for a period of observation regardless of cyst size or complex characteristics[12]. Parents should be educated on signs and symptoms of torsion and when to return to the office or emergency department with their infant. Cysts being followed by serial ultrasound that demonstrate any enlargement or evidence of gastrointestinal or genitourinary abnormalities should be considered for surgical exploration. Persistent or symptomatic ovarian cysts in the newborn can be treated by aspiration, marsupialization, unroofing, or excision with the intent of organ salvage by either laparoscopy or open exploration.

### **Fetal Retroperitoneal Masses**

Retroperitoneal masses are uncommonly found *in utero* and rarely, if ever, require direct fetal intervention; however, when a retroperitoneal mass is diagnosed, it is important to think of an appropriate differential diagnosis so that appropriate work-up, counseling and management occur depending on the diagnosis. Appropriate adrenal pathology to consider includes adrenal hematoma, neuroblastoma and rarely a second hydronephrotic collecting system or liver mass may be confused with an adrenal mass. Renal pathology includes mesoblastic nephroma, Wilms' tumor (rare), multicystic dysplastic kidney and of course other urinary collecting system pathologies such as hydronephrosis, infantile polycystic kidney disease (autosomal recessive), Meckel-Gruber syndrome, benign glomerulosclerosis, adult dominant polycystic kidney disease, trisomy 13, Beckwith-Weidemann syndrome and Perlman syndrome[11]. Other diagnoses to be considered when a retroperitoneal mass is noted include extra-lobar pulmonary

sequestration, ovarian masses, fetus-in-fetu and choledochal cysts. These should be considered in the differential during counseling and subsequent fetal ultrasounds. There is very little data regarding direct fetal intervention for these pathologies. If the adrenal hemorrhage was moderate to severe, then this should prompt the mother to deliver at a facility that can manage neonatal shock. Congenital mesoblastic nephroma is a massive, usually benign hamartomatous, solitary renal tumor that rarely has malignant degeneration. Risks to the fetus include prematurity and polyhydramnios, and this influences post-natal outcome. In all renal tumors, liver metastasis and locoregional lymph nodes should be evaluated also. Although hydrops fetalis, dystocia and tumor rupture have all been reported, fetal intervention is not considered standard therapy, although every case should be evaluated independently. We would advocate for delivery at a tertiary center capable of caring for neonatal cardiopulmonary compromise. After appropriate neonatal resuscitation, gentle ventilation techniques, and radiological imaging, standard of care is complete surgical resection. Chemotherapy and radiation is rarely needed for mesoblastic nephroma. Wilms' tumor is extremely rare in fetuses and it has an excellent prognosis when diagnosed prenatally or within the first month of life. Standard work-up and resection should occur. Neuroblastoma can cause elevated maternal catecholamine metabolites and maternal antenatal symptoms; however, no direct fetal intervention is needed other than early delivery for fetal compromise or maternal distress. As with other retroperitoneal solid tumors, polyhydramnios and fetal hydrops have been reported as well as hemorrhage during vaginal delivery, therefore cesarean section should be considered. Standard post-natal work-up should occur followed by appropriate risk-stratified therapy. Neuroblastomas diagnosed *in utero* or within the first weeks of life have a significantly better prognosis than neuroblastoma diagnosed after 18 months and many (including 4S metastatic neuroblastoma) regress spontaneously. Consultation with a pediatric oncologist is recommended before offering final therapeutic decisions to a family. Fetus-in-fetu is a rare congenital condition in which a fetiform mass is detected in the fetal retroperitoneum but can also be detected in the fetal chest, head and neck[13]. These lesions may present as abdominal cystic masses with ascites and can be difficult to discern from meconium peritonitis. Diagnosis is made by the findings of a diminutive fetal vertebra column. Fetal intervention is not likely warranted, however postnatal imaging would be recommended to further delineate prior to surgical intervention[13]. These lesions can be distinguished from teratomas and are uniformly benign. Interestingly, the pediatric surgeon should be aware that the blood supply to intra-abdominal fetus-in-fetu lesions may arise from the host superior mesenteric artery, a fact which might aid in diagnosis and potentially complicate resection of the lesion[14].

### **Fetal Intracardiac and Pericardial Neoplasms**

Cardiac neoplasms are exceedingly rare with an incidence of approximately 0.1%[15]. The most common histologic type is a rhabdomyoma which accounts for three-quarters of cardiac neoplasms and can be multi-focal[16]. When rhabdomyoma is suspected, tuberous sclerosis as an underlying disorder should be considered and warrants careful evaluation of the fetus for other anomalies associated with this disorder such as renal lesions and intracranial anomalies[17]. Other sub-types include teratoma, fibroma, vascular malformations and

myxoma[16]. Cardiac lesions usually are detectable after 22 weeks gestation on prenatal ultrasound and can involve the pericardium, myocardium, cardiac valves and/or the major pericardial blood vessels[18, 19]. The outcome for cardiac neoplasms is grim with a risk for IUFD as high as 57%[16]. Even if the fetus survives to delivery, the mass appears to stabilize or even regress, the mortality rate in the first year of life is as high as 80%[20]. Once diagnosed, the presence of non-immune hydrops should be sought by ultrasound and dedicated fetal echocardiography. Findings of hydrops include polyhydramnios, placentomegaly, fetal skin and scalp edema and accumulation of fluid in the pleural, pericardial or peritoneal spaces. By definition, fetal hydrops is present when two or more compartments are affected (i.e., scalp edema and abdominal ascites). Left untreated, fetal hydrops is frequently fatal[21, 22]. Experts (Level of Evidence: 5) have considered the presence of non-immune hydrops an indication to offer therapy[23]. In the setting of hydrops developing during the third trimester, an EXIT to resection of the mass may be indicated[23]. Fetal surgical resection of the mass and drainage of the effusion through a maternal hysterotomy and fetal median sternotomy at 24 weeks gestation has been described having an excellent outcome[23].

### **Level of Evidence**

Grade B, Level 3a/3b (case-control studies) unless otherwise stated

## References

- [1] Gerscovich EO, Sekhon S, Loehfelm TW, Wootton-Gorges SL, Greenspan A. A reminder of peristalsis as a useful tool in the prenatal differential diagnosis of abdominal cystic masses. *Journal of ultrasonography* 2017;17(69):129-32.
- [2] Cystic lesions of the abdomen. In: Bianchi DW CT, D'Alton ME, Malone FD, eds., editor *Fetology: Diagnosis and Management of the Fetal Patient*. New York, NY: McGill-Hill; 2010, p. 461-4.
- [3] Chen M, Ho WK, Hsieh TC, Lee CS, Hsiao CC, Chang SP, et al. Huge duplication cyst of small intestine: ultrasonographic features and prenatal aspiration. *Prenatal diagnosis* 2006;26(1):86-8.
- [4] Pryse-Davies J, Dewhurst CJ. The development of the ovary and uterus in the foetus, newborn and infant: a morphological and enzyme histochemical study. *The Journal of pathology* 1971;103(1):5-25.
- [5] Rizzo N, Gabrielli S, Perolo A, Pilu G, Cacciari A, Domini R, et al. Prenatal diagnosis and management of fetal ovarian cysts. *Prenatal diagnosis* 1989;9(2):97-103.
- [6] Nussbaum AR, Sanders RC, Hartman DS, Dudgeon DL, Parmley TH. Neonatal ovarian cysts: sonographic-pathologic correlation. *Radiology* 1988;168(3):817-21.
- [7] Trinh TW, Kennedy AM. Fetal ovarian cysts: review of imaging spectrum, differential diagnosis, management, and outcome. *Radiographics : a review publication of the Radiological Society of North America, Inc* 2015;35(2):621-35.
- [8] Sakala EP, Leon ZA, Rouse GA. Management of antenatally diagnosed fetal ovarian cysts. *Obstetrical & gynecological survey* 1991;46(7):407-14.
- [9] Valenti C KE, Yermakov V, et. al. Antenatal diagnosis of a fetal ovarian cyst. *American journal of obstetrics and gynecology* 1975;15:216.
- [10] Crombleholme TM, Craigo SD, Garmel S, D'Alton ME. Fetal ovarian cyst decompression to prevent torsion. *Journal of pediatric surgery* 1997;32(10):1447-9.
- [11] Gorincour G, Dugougeat-Pilleul F, Bouvier R, Lorthoix-Ninou S, Devonec S, Gaucherand P, et al. Prenatal presentation of cervical congenital neuroblastoma. *Prenatal diagnosis* 2003;23(8):690-3.
- [12] Papic JC, Billmire DF, Rescorla FJ, Finnell SM, Leys CM. Management of neonatal ovarian cysts and its effect on ovarian preservation. *Journal of pediatric surgery* 2014;49(6):990-3; discussion 3-4.
- [13] Kim YJ, Sohn SH, Lee JY, Sohn JA, Lee EH, Kim EK, et al. Misdiagnosis of fetus-in-fetu as meconium peritonitis. *Korean journal of pediatrics* 2011;54(3):133-6.
- [14] Grosfeld JL, Stepita DS, Nance WE, Palmer CG. Fetus-in-fetu: An unusual cause for abdominal mass in infancy. *Annals of surgery* 1974;180(1):80-4.
- [15] Groves AM, Fagg NL, Cook AC, Allan LD. Cardiac tumours in intrauterine life. *Archives of disease in childhood* 1992;67(10 Spec No):1189-92.
- [16] Holley DG, Martin GR, Brenner JI, Fyfe DA, Huhta JC, Kleinman CS, et al. Diagnosis and management of fetal cardiac tumors: a multicenter experience and review of published reports. *Journal of the American College of Cardiology* 1995;26(2):516-20.
- [17] Kwiatkowski DJ, Short MP. Tuberous sclerosis. *Archives of dermatology* 1994;130(3):348-54.
- [18] Brackley KJ, Farndon PA, Weaver JB, Dow DJ, Chapman S, Kilby MD. Prenatal diagnosis of tuberous sclerosis with intracerebral signs at 14 weeks' gestation. *Prenatal diagnosis* 1999;19(6):575-9.
- [19] Gava G, Buoso G, Beltrame GL, Memo L, Visentin S, Cavarzerani A. Cardiac rhabdomyoma as a marker for the prenatal detection of tuberous sclerosis. Case report. *British journal of obstetrics and gynaecology* 1990;97(12):1154-7.

- [20] Green KW, Bors-Koefoed R, Pollack P, Weinbaum PJ. Antepartum diagnosis and management of multiple fetal cardiac tumors. *Journal of ultrasound in medicine : official journal of the American Institute of Ultrasound in Medicine* 1991;10(12):697-9.
- [21] Adzick NS, Harrison MR, Glick PL, Golbus MS, Anderson RL, Mahony BS, et al. Fetal cystic adenomatoid malformation: prenatal diagnosis and natural history. *Journal of pediatric surgery* 1985;20(5):483-8.
- [22] Adzick NS. Open fetal surgery for life-threatening fetal anomalies. *Seminars in fetal & neonatal medicine* 2010;15(1):1-8.
- [23] Rychik J, Khalek N, Gaynor JW, Johnson MP, Adzick NS, Flake AW, et al. Fetal intrapericardial teratoma: natural history and management including successful in utero surgery. *American journal of obstetrics and gynecology* 2016;215(6):780.e1-.e7.



## **Prenatal Diagnosis and Therapy for Myelomeningocele**

**Mitchell R. Ladd, Nathan Heinzerling, Amy J. Wagner, Eric B. Jelin**

### **Introduction**

Myelomeningocele is a congenital defect that results from incomplete closure of the neural tube during development. Myelomeningocele is the most common non-lethal neural tube defect with a current estimated prevalence of 1.9-3.8 per 10,000 live births [1–5]. Incomplete closure has two consequences: an open spinal canal with exposed neural tissue and leakage of cerebrospinal fluid. The incidence of neural tube defects has decreased since the United States mandated fortification of grain products with folic acid. Unfortunately, folic acid supplementation has not eradicated the anomaly suggesting a multifactorial cause including exposure to drugs, toxins, and genetic abnormalities [4,6,7].

### **Associated Complications**

Patients with myelomeningocele display a wide array of abnormalities related to the severity of their neurologic defect and are at risk for numerous complications throughout their life. This has inspired research into treating the myelomeningocele defect early to prevent or decrease the morbidity associated with the exposed neural placode.

Virtually all newborns with a myelomeningocele defect develop an Arnold-Chiari II malformation. The pressure gradient from continued leakage of cerebrospinal fluid results in hindbrain herniation. Of the patients with Arnold-Chiari II malformation, more than 90% will develop hydrocephalus [7–9]. Before the advent of ventriculoperitoneal shunting, hydrocephalus was the main cause of mortality among these patients. Even with shunting, children are still at risk for cerebellar and upper cervical nerve dysfunction resulting in a dysfunction of swallowing, vocal cord motion, upper extremity innervation, and in severe cases, central hypoventilation or apnea. Additionally, patients with myelomeningocele have difficulty with bowel and bladder control due to nerve dysfunction of the distal bowel, anal sphincter, bladder, and internal and external bladder sphincters. Poor outcomes are seen in patients who suffer from bladder sphincter dysynergy. These patients suffer from vesicoureteral reflux, which damages the upper urinary tract and may lead to renal failure. This can be abrogated by clean intermittent catheterization to prevent reflux [7,10].

### **Mechanism of Injury**

The wide spectrum of neurologic deficits and associated morbidity from myelomeningocele can be explained by a “two-hit hypothesis” of injury. The first hit is the abnormality of the neural placode itself resulting in the defect. The second hit of myelomeningocele injury is the continued

exposure of the neural tissue to amniotic fluid and intrauterine trauma throughout fetal development [11,12]. The two-hit model is supported by observations in human and animal development. First, patients with milder forms of neural tube defects in which the neural elements remain covered by skin or a membrane show improved neurologic development [13]. Also, studies in both humans and mice with a myelomeningocele show near normal hind limb movement in early development with progressive loss of function in utero as pregnancy progresses [14–16].

Animal models of surgically created myelomeningoceles in rodents, sheep, rabbits and nonhuman primates show a similar phenotype to that seen in humans. When the defects are surgically closed prenatally, there is marked improvement in motor and urinary function and reversal of the Arnold-Chiari malformation with near normal hindbrain development in the animal model [17]. This observation was important in the development of techniques to repair myelomeningoceles in utero and mitigate the effects of the second hit.

### **Fetoscopic Repair**

Early attempts at prenatal repair of a myelomeningocele with fetoscopy were by Vanderbilt Medical Center and the University of California, San Francisco [UCSF] [18–20]. Vanderbilt reported four cases of application of a maternal skin graft over the defect using a maternal laparotomy and three-port access to the uterus. Two of the fetuses survived to birth, however, both required reoperation as there was no skin graft present at birth. The University of California group reported three attempts at fetoscopic repair, two of which were converted to open repair due to intraoperative difficulties. The final patient had their defect covered with a decellularized dermal matrix. At birth, there was incomplete coverage of the myelomeningocele defect requiring reoperation.

In an effort to standardize the fetal repair surgery, and due to the relatively poor outcomes of fetoscopic repair, open repair was used as the standard approach in the subsequent clinical trial (refer to next section) [21,22]. However, in Europe, fetoscopic approaches were still used and there is interest in refining these techniques in an effort to reduce the complications that rise from premature birth often seen with open repairs [22]. After the Management of Myelomeningocele Study (MOMS), there was renewed interest to re-evaluate fetoscopic approaches to reduce the risk of maternal complications and fetal prematurity. A recent meta-analysis was performed by Kabagambe *et al.* to compare open and fetoscopic approaches to myelomeningocele repair [22]. This analysis included 11 studies in the final data and found that fetoscopic repairs were less likely to be completed via intended surgical approach (90-92% for fetoscopic vs. 99.8% open), have higher rates of myelomeningocele defect treatment after birth (28-30% fetoscopic vs. 7%), higher rates of preterm birth (defined as less than 37 weeks gestation; 90-96% vs. 81%), premature rupture of membranes (79-91% vs. 36%), and finally lower rates of uterine dehiscence (0% vs. 11%) [22]. The authors concluded that while the fetoscopic approach to myelomeningocele repair is promising and has lower uterine dehiscence rates, the technique should be improved before it can be a viable alternative to the gold standard open repair. Another potential advantage of a fetoscopic approach is the ability to deliver vaginally.

This was demonstrated in a series of women who underwent fetoscopic endotracheal occlusion for congenital diaphragmatic hernia [23].

### **Open Repair and the MOMS Trial**

One of the first reports of open fetal myelomeningocele repair was published by Vanderbilt University in 1999. This study compared open repairs with historical controls and found improved hindbrain herniation with fetal repair and a decreased need for ventriculoperitoneal shunting [24]. UCSF and Children's Hospital of Philadelphia (CHOP) also found fetal surgery reduced hindbrain herniation, improved Arnold-Chiari malformations, and had a decreased need for ventriculoperitoneal shunting [20,25]. Despite these initial promising results, further studies showed mixed results regarding neurologic outcomes in these patients [26,27].

With unclear benefit to the child and risks of placental abruption, uterine dehiscence and preterm labor, further studies were needed to evaluate whether fetal surgery would provide benefit over postnatal myelomeningocele repair. In 2003, the UCSF, CHOP, Vanderbilt University, and George Washington University collaborated with the National Institute of Health to conduct a randomized controlled study comparing fetal versus postnatal myelomeningocele repair (the MOMS trial). Their goal was to enroll 200 patients at gestational age 19 to 25 weeks with myelomeningocele defects between T1 and S1. The patients were randomized to open fetal repair of the myelomeningocele or repair after delivery. All patients undergoing fetal surgery underwent cesarean section at 37 weeks gestation to prevent the risk of uterine dehiscence. Enrollment for the study was stopped in December 2010 by the data safety monitoring committee due to the efficacy of prenatal surgery shown in the first 183 patients [28].

There were two primary outcomes in the study. The first was a composite of the following: fetal or neonatal death or the need for a ventriculoperitoneal shunt by 12 months of age. The second primary outcome, measured at 30 months, was a composite of the Mental Development Index of Bayley Scales of Infant Development II and the child's motor function with adjustment for lesion level [28]. The first analysis of the MOMS trial included the 12-month outcomes for only 158 infants and 30-month outcomes for 134 of the infants [29,30]. There were no maternal deaths and two perinatal deaths in each group. The need for ventriculoperitoneal shunting (based on the predefined criteria regardless of actual shunt placement) in the prenatal and postnatal surgery groups at 12 months of age were 68% and 98%, respectively ( $p < 0.001$ ). Actual shunt placement was 40% in the prenatal group and 82% in the post-natal group ( $p < 0.001$ ). The second primary outcome showed significant functional and neurologic improvement at 30 months of age in the prenatal surgery group ( $p = 0.007$ ).

The prenatal surgery group had numerous other benefits in post hoc analyses. The most notable include an improved ability to walk without devices or orthotics in the prenatal surgery group (42% versus 21%,  $p = 0.01$ ) and decreased hindbrain herniation at 12 months in the prenatal surgery group (64% versus 96%,  $p < 0.001$ ). Additionally, even though the prenatal surgery group had more severe anatomical lesion levels, they had better motor function than the postnatal surgery group when measured with either the Bayley or Peabody motor scales. Significant

maternal morbidity related to prenatal surgery included uterine dehiscence, oligohydramnios, placental abruption, spontaneous rupture of membranes, and chorioamniotic separation.

In 2015, the final results of the initial MOMS study were published for all 183 patients [30]. In the full cohort, the primary outcome of death or need for shunt was 73% of the prenatal surgery group compared to 98% of the post-natal repair group [30]. Actual shunt placement rates for prenatal compared to postnatal repair groups were 44% and 84% respectively [30]. Given that the management of hydrocephalus had evolved over time during the MOMS trial, in the full cohort, the group revised their objective criteria for meeting shunt placement and re-analyzed the data using a revised primary outcome. When the revised primary outcome was measured, fetal death or the need for shunt placement by the new criteria was only 49.5% of prenatal surgery patients compared to 87% in the postnatal group. The number of children who received a shunt and required revision by 1 year was lower in the prenatal surgery group (15.4% vs. 40.2%). Finally, the study found that a larger ventricle size at initial screening was associated with increased need for a shunt. Regardless of ventricle size, there were higher rates of shunting in the postnatal repair group (ventricle size < 10mm had 20% shunt rate in prenatal repair vs. 79.4% for postnatal repair, for size 10-15 mm 45.2% vs. 86%, and for size greater than 15 mm 79% vs. 87.5%). The conclusion from the final published results was that fetuses with ventricle size < 10 mm at diagnosis are ideal candidates for fetal repair whereas in those fetuses with ventricles greater than 15 mm, there does not seem to be a benefit of fetal surgery related to shunting [30]. Whether fetuses with ventricle sizes greater than 15 mm at diagnosis would receive other benefits from prenatal repair remains to be answered. The long-term outcomes of these children continue to be monitored in the ongoing MOMS II study.

A sub-study analysis of urologic function was conducted by Brock *et al.* and included 115 women. The primary outcome was need for clean intermittent catheterization at 30 months with secondary outcomes of bladder and kidney abnormalities as determined by urodynamic and ultrasound studies [31]. Prenatal surgery did not reduce the need for clean intermittent catheterization (52% of patients in the prenatal surgery group compared to 66% of the postnatal group). However, the authors did find that prenatal surgery was associated with less bladder trabeculation and fewer cases of open bladder neck.

The investigators at CHOP have published their experience since the end of the MOMS trial [29,21]. They have performed more than 190 closures since the end of the trial and have reported the results of the first 100 of those cases. Overall, results between the MOMS trial and the Philadelphia experience are similar. Several key differences in the Philadelphia experience after the MOMS trial were: earlier gestational age at surgery (23.3 vs. 23.6 weeks), more frequent L3/L4 level lesions (66% vs. 38%), less frequent L5/S1 lesions (7% vs. 29%), lower rate of preterm premature rupture of membranes (32% vs. 46%), lower rates of maternal pulmonary edema (2% vs. 6%; likely due to change in perioperative management including increased oral fluid intake the night prior to surgery and intravenous fluid restriction during and for 24 hours after surgery), lower need for maternal blood transfusion (3% vs. 9%), and lower rate of dehiscence at the fetal repair site (3.6% vs. 13%). The neonatal results from the Philadelphia group are promising, but the 12 month outcomes are not yet published. The authors did find a higher apnea rate of 58%

in their cohort compared to 36% in the MOMS trial which they attributed to the fact that at their center, all neonates undergoing prenatal repair, regardless of gestational age at delivery, undergo intensive care monitoring which may have diagnosed apnea that might have otherwise gone unrecognized in the MOMS trial. Finally, the perinatal mortality rate in the Moldenhauer series was 6% compared to 3% in the MOMS trial which the authors suggest may have been due to the slightly earlier age of prenatal repair compared to the MOMS trial [29,21].

Vanderbilt has also published a series of 43 patients since the MOMS trial ended in which they used a slightly modified surgical technique that minimizes the separation of the amniotic membrane [32]. Bennet *et al.* compared this cohort to a cohort of 78 patients treated during the MOMS trial and found several improvements in outcomes with the modified surgical technique. Preterm labor and delivery was 22% with no chorioamnion separation observed in the modified technique group compared to 46% preterm labor and delivery and 26% chorioamnion separation in the MOMS cohort. The mean gestational age at delivery was similar between the two groups (34.4 weeks in modified technique group compared to 34.1 weeks in MOMS cohort), but a higher proportion of infants in the modified technique group were born at 37 weeks or greater compared to the MOMS group (39% vs. 21%). Importantly, fetal mortality (5% mortality in the modified technique vs. 3% in MOMS cohort) and shunt rates (41% in modified technique vs. 40% in the MOMS group) did not differ between groups [32].

St. Louis Fetal Care Institute is the first center not involved in the MOMS trial to publish outcomes on the first 60 patients they treated [33]. The St. Louis group strictly followed the MOMS trial inclusion and exclusion criteria. In addition, based on the publication of the full MOMS cohort by Tulipan *et al.*, they also excluded fetuses with ventricle size greater than or equal to 15 mm at the time of diagnosis [30,33]. In the 60 patients, there were no maternal nor intra-operative or postoperative fetal mortalities. The mean gestational age at delivery was 34 weeks with greater than 60% of patients delivered at greater than or equal to 36 weeks of gestation which was similar to the outcomes in the MOMS trial. At the time of publication, 58 neonates had been born and 2 died in the neonatal period due to prematurity. One additional patient was excluded due to lack of consent for research leaving 55 patients for evaluation in the study. The authors also investigated the use of endoscopic third ventriculostomy (ETV) for management of hydrocephalus as an alternative to ventriculoperitoneal shunting. Elbabaa *et al.* defined the indication for cerebrospinal fluid diversion as macrocrania, signs of increased intracranial pressure (bulging fontanelle, apnea, bradycardia) associated with ventriculomegaly, and/or progressive syringomyelia [33]. Thirty infants (54.5%) underwent treatment for symptomatic hydrocephalus (either ETV or shunting) which is higher than the shunt rate in the MOMS trial (40%). Six infants underwent ventriculoperitoneal shunting as primary management of symptomatic hydrocephalus and 24 infants underwent ETV as initial treatment. The success rate of ETV was 45.8% (11/24). Failure of ETV was defined as the progression to ventriculoperitoneal shunting which occurred in 13 of the patients that initially underwent ETV. The shunt rate in the St. Louis cohort was 34.5% in total, when counting the 13 failures from ETV with the 6 infants that underwent primary shunting. This is lower than the 40% shunt rate in the MOMS trial. Thus, while the St. Louis group treated a higher percentage of patients for symptomatic hydrocephalus, they had a lower shunt rate due to the successful use of ETV in some patients. When evaluating

factors that predicted success or failure of ETV in patients that had undergone prenatal repair, the authors found that in-utero stability of ventricle size less than 4 mm and in-utero ventricle size post-repair of less than or equal to 15.5 mm were associated with success while age less than 6 months at the time of ETV and gestational age greater than 23 weeks at the time of fetal repair were associated with ETV failure [33].

Due to the increasing demand and utility of prenatal repair of myelomeningocele, a position statement from the fetal myelomeningocele Maternal-Fetal Management Task Force was published that provides guidelines for key clinical practice components that should be in place to perform these surgeries [34]. In addition, a Fetal Myelomeningocele Consortium has created a registry as part of the North American Fetal Therapy Network (NAFTNet) to track outcomes and guide future research [21].

Finally, more recent concerns have arisen regarding repeat pregnancies in women that have undergone open fetal repair of myelomeningocele. When analyzing women from the MOMS trial that underwent fetal repair, the uterine dehiscence rate was 12.5% during subsequent deliveries [21,35]. Another study by Wilson *et al.* looked at subsequent pregnancy outcomes by evaluating questionnaires from women that underwent open fetal surgery for various diagnoses. This study found that while fertility seemed to be unaffected by open fetal surgery, uterine rupture occurred in 14% and uterine dehiscence in 14% of women. Unfortunately, conclusive data about these outcomes and an evidence-based guideline for how to monitor the prior hysterotomy site during a subsequent pregnancy do not exist. However, as proposed by Moldenhauer *et al.*, best practice recommendations currently consist of serial ultrasound exams of the prior hysterotomy site, prompt assessment with development of any maternal symptoms, and cesarean delivery at 37 weeks [21]. In addition, Moldenhauer *et al.* recommend an interval of at least 2 years between pregnancies after open fetal surgery.

### **Summary**

The *in utero* treatment of myelomeningocele contributes to improved outcomes in children with reduction of hindbrain herniation, less need for VP shunts, and enhanced motor outcomes, especially in fetuses with ventricle size less than 10 mm at prenatal diagnosis. Further research and improved techniques are still needed to minimize the risks to both the fetus and mother, especially as it relates to the fetoscopic approach to myelomeningocele repair. In addition, future research should evaluate the outcomes of mothers that go on to have multiple children after open fetal repair. Because this is the first non-lethal indication for fetal surgery, we must strive for improved outcomes and minimize the morbidity to both the fetus and mother. Other future directions include the use of stem cells or biomaterials to improve neurologic outcomes and provide improved coverage during fetal myelomeningocele repair [36,37]. Finally, published guidelines now exist to assist in developing prenatal myelomeningocele clinical programs and all cases should be entered into the Fetal Myelomeningocele Consortium.

**Level of Evidence**

Open MMC repair = Grade A, Level 1 (Randomized controlled trial)

Fetoscopic MMC repair = Grade B, level 3 (meta-analysis of cohort studies)

Maternal outcomes = Grade B, level 3 (case-control)

Based on the Oxford 2011 Levels of Evidence, the evidence for the majority of the open fetal repair of myelomeningocele data is level 2 due to the well-designed randomized clinical trial (MOMS Trial) [38]. The data for fetoscopic myelomeningocele is level 3 evidence due to the well-organized meta-analysis of cohort studies. by Kabagambe *et al.* The studies of fetal repair outcomes after the MOMS trial are level 3 evidence.

## References

- [1] Parker SE, Mai CT, Canfield MA, Rickard R, Wang Y, Meyer RE, et al. Updated national birth prevalence estimates for selected birth defects in the United States, 2004-2006. *Birth Defects Res Part A - Clin Mol Teratol* 2010;88:1008–16. doi:10.1002/bdra.20735.
- [2] Bowman RM, Boshnjaku V, McLone DG. The changing incidence of myelomeningocele and its impact on pediatric neurosurgery: A review from the children's memorial hospital. *Child's Nerv Syst* 2009;25:801–6. doi:10.1007/s00381-009-0865-z.
- [3] Canfield MA, Honein MA, Yuskiv N, Xing J, Mai CT, Collins JS, et al. National estimates and race/ethnic-specific variation of selected birth defects in the United States, 1999-2001. *Birth Defects Res Part A - Clin Mol Teratol* 2006;76:747–56. doi:10.1002/bdra.20294.
- [4] Boulet SL, Yang Q, Mai C, Kirby RS, Collins JS, Robbins JM, et al. Trends in the postfortification prevalence of spina bifida and anencephaly in the United States. *Birth Defects Res Part A - Clin Mol Teratol* 2008;82:527–32. doi:10.1002/bdra.20468.
- [5] Data and Statistics | Spina Bifida | NCBDDD | CDC n.d. <https://www.cdc.gov/ncbddd/spinabifida/data.html> (accessed October 29, 2017).
- [6] Findley TO, Tenpenny JC, O'Byrne MR, Morrison AC, Hixson JE, Northrup H, et al. Mutations in folate transporter genes and risk for human myelomeningocele. *Am J Med Genet Part A* 2017;173:2973–84. doi:10.1002/ajmg.a.38472.
- [7] Heinzerling N, Wagner A. *Fetal Diagnosis and Therapy: A Reference Handbook for Pediatric Surgeons*. American Pediatric Surgical Association; 2013.
- [8] Steinbok P, Irvine B, Douglas Cochrane D, Irwin BJ. Long-term outcome and complications of children born with meningomyelocele. *Child's Nerv Syst* 1992;8:92–6. doi:10.1007/BF00298448.
- [9] Woodhouse CRJ. Myelomeningocele: Neglected aspects. *Pediatr Nephrol* 2008;23:1223–31. doi:10.1007/s00467-007-0663-3.
- [10] Shaer CM, Chescheir N, Schulkin J. Myelomeningocele: a review of the epidemiology, genetics, risk factors for conception, prenatal diagnosis, and prognosis for affected individuals. *Obstet Gynecol Surv* 2007;62:471–9. doi:10.1097/01.ogx.0000268628.82123.90.
- [11] Korenromp M, Van Gool J, Bruinese H, Kriek R. Early Fetal Leg Movements in Myelomeningocele. *Lancet* 1986;327:917–8. doi:10.1016/S0140-6736(86)91022-6.
- [12] Saadai P, Farmer DL. Fetal Surgery for Myelomeningocele. *N Engl J Med* 2012;39:279–88. doi:10.1056/NEJMoa1014379. Copyright.
- [13] Oya N, Suzuki Y, Tanemura M, Kojima K, Kajiura S, Murakami I, et al. Detection of skin over cysts with Spina bifida may be useful not only for preventing neurological damage during labor but also for predicting fetal prognosis. *Fetal Diagn Ther* 2000;15:156–9. doi:20996.
- [14] Juliá V, Sancho MA, Albert A, Conill J, Martínez A, Grande C, et al. Prenatal covering of the spinal cord decreases neurologic sequelae in a myelomeningocele model. *J Pediatr Surg* 2006;41:1125–9. doi:10.1016/j.jpedsurg.2006.02.005.
- [15] Stiefel D, Copp AJ, Ph D, Meuli M. Fetal spina bifida : Loss of neural function in utero. *J Neurosurg* 2013;106:213–21. doi:10.3171/ped.2007.106.3.213.Fetal.
- [16] Hutchins GM, Meuli M, Meuli-Simmen C, Jordan MA, Heffez DS, Blakemore KJ. Acquired spinal cord injury in human fetuses with myelomeningocele. *Pediatr Pathol Lab Med* n.d.;16:701–12.
- [17] Paek BW, Farmer DL, Wilkinson CC, Albanese CT, Peacock W, Harrison MR, et al. Hindbrain herniation develops in surgically created myelomeningocele but is absent after repair in fetal lambs. *Am J Obstet Gynecol* 2000;183:1119–23.



- doi:10.1067/mob.2000.108867.
- [18] Bruner JP, Richards WO, Tulipan NB, Arney TL. Endoscopic coverage of fetal myelomeningocele in utero. *Am J Obstet Gynecol* 1999;180:153–8. doi:10.1016/S0002-9378(99)70167-5.
- [19] Bruner JP, Tulipan NB, Richards WO, Walsh WF, Boehm FH, Vrabcak EK. In utero repair of myelomeningocele: a comparison of endoscopy and hysterotomy. *Fetal Diagn Ther* 2000;15:83–8. doi:10.1159/000020981.
- [20] Farmer D I., von Koch CS, Peacock WJ, Danielpour M, Gupta N, Lee H, et al. In utero repair of myelomeningocele. *Arch Surg* 2003;138:872. doi:10.1001/archsurg.138.8.872.
- [21] Moldenhauer JS, Adzick NS. Fetal surgery for myelomeningocele: After the Management of Myelomeningocele Study (MOMS). *Semin Fetal Neonatal Med* 2017;1–7. doi:10.1016/j.siny.2017.08.004.
- [22] Kabagambe SK, Jensen GW, Chen YJ, Vanover MA, Farmer DL. Fetal Surgery for Myelomeningocele: A Systematic Review and Meta-Analysis of Outcomes in Fetoscopic versus Open Repair. *Fetal Diagn Ther* 2017;95817. doi:10.1159/000479505.
- [23] Gregoir C, Engels AC, Gomez O, DeKoninck P, Lewi L, Gratacos E, et al. Fertility, pregnancy and gynecological outcomes after fetoscopic surgery for congenital diaphragmatic hernia. *Hum Reprod* 2016;31:2024–30. doi:10.1093/humrep/dew160.
- [24] Bruner JP, Tulipan N, Paschall RL, Boehm FH, Walsh WF, Silva SR, et al. Fetal surgery for myelomeningocele and the incidence of shunt-dependent hydrocephalus. *JAMA J Am Med Assoc* 1999;282:1819–25. doi:10.1001/jama.282.19.1819.
- [25] Sutton LN, Adzick NS, Bilaniuk LT, Johnson MP, Crombleholme TM, Flake AW. Improvement in hindbrain herniation demonstrated by serial fetal magnetic resonance imaging following fetal surgery for myelomeningocele. *Jama* 1999;282:1826–31. doi:10.1001/jama.282.19.1826.
- [26] Tulipan N, Bruner JP, Hernanz-Schulman M, Lowe LH, Walsh WF, Nickolaus D, et al. Effect of intrauterine myelomeningocele repair on central nervous system structure and function. *Pediatr Neurosurg* 1999;31:183–8. doi:10.1159/000028859.
- [27] Tulipan N, Bruner JP. Myelomeningocele repair in utero: a report of three cases. *Pediatr Neurosurg* 1998;28:177–80.
- [28] Adzick NS, Thom EA, Spong CY, Brock III JW, Burrows PK, Johnson MP, et al. A Randomized Trial of Prenatal versus Postnatal Repair of Myelomeningocele. *N Engl J Med* 2011;364:993–1004.
- [29] Moldenhauer JS, Soni S, Rintoul NE, Spinner SS, Khalek N, Martinez-Poyer J, et al. Fetal myelomeningocele repair: The post-MOMS experience at the children’s hospital of Philadelphia. *Fetal Diagn Ther* 2015;37:235–40. doi:10.1159/000365353.
- [30] Tulipan N, Wellons II JC, Thom EA, Gupta N, Sutton LN, Burrows PK, et al. Prenatal surgery for myelomeningocele and the need for cerebrospinal fluid shunt placement. *J Neurosurg Pediatr* 2015;16:613–20. doi:10.3.171.
- [31] Brock JW, Carr MC, Adzick NS, Burrows PK, Thomas JC, Thom EA, et al. Bladder Function After Fetal Surgery for Myelomeningocele. *Pediatrics* 2015;136:e906–13. doi:10.1542/peds.2015-2114.
- [32] Bennett KA, Carroll MA, Shannon CN, Braun SA, Dabrowiak ME, Crum AK, et al. Reducing perinatal complications and preterm delivery for patients undergoing in utero closure of fetal myelomeningocele: further modifications to the multidisciplinary surgical technique. *J Neurosurg Pediatr* 2014;14:108–14. doi:10.3171/2014.3.PEDS13266.
- [33] Elbabaa SK, Gildehaus AM, Pierson MJ, Albers JA, Vlastos EJ. First 60 fetal in-utero myelomeningocele repairs at Saint Louis Fetal Care Institute in the post-MOMS trial era: hydrocephalus treatment outcomes (endoscopic third ventriculostomy versus ventriculo-peritoneal shunt). *Child’s Nerv Syst* 2017;33:1157–68. doi:10.1007/s00381-017-3428-8.
- [34] Cohen AR, Couto J, Cummings JJ, Johnson A, Joseph G, Kaufman BA, et al. Position

- statement on fetal myelomeningocele repair. *Am J Obstet Gynecol* 2014;210:107–11.  
doi:10.1016/j.ajog.2013.09.016.
- [35] Thom E a. 50: Maternal reproductive outcomes after in-utero repair of myelomeningocele. *Am J Obstet Gynecol* 2016;214:S36.  
doi:10.1016/j.ajog.2015.10.067.
- [36] Sanchez e Oliveira RDC, Valente PR, Abou-Jamra RC, Araújo A, Saldiva PH, Pedreira DAL. Biosynthetic cellulose induces the formation of a neoduramater following pre-natal correction of meningomyelocele in fetal sheep. *Acta Cir Bras* 2007;22:174–81.  
doi:10.1590/S0102-86502007000300004.
- [37] Fauza DO, Jennings RW, Teng YD, Snyder EY. Neural stem cell delivery to the spinal cord in an ovine model of fetal surgery for spina bifida. *Surgery* 2008;144:367–73.  
doi:10.1016/j.surg.2008.05.009.
- [38] OCEBM Levels of Evidence Working Group. *The Oxford 2011 Levels of Evidence*. Oxford Cent Evidence-Based Med 2011.

## Abdominal Wall Defects

Erin E. Perrone, MD, Fuad Alkhoury, MD, and Shaheen Timmapuri, MD

### Introduction

Abdominal wall defects are a common prenatal consult for a pediatric surgeon to see. Gastroschisis and omphalocele are the two most common defects and are often detected with both routine maternal serum screening (both have elevated AFP) and fetal ultrasound (1, 2). Gastroschisis is defined as an abdominal wall defect just right of the midline and umbilical cord in which the bowel is herniated without a covering sac (3). This is differentiated from omphalocele which has a midline defect typically with a membranous sac covering that is enclosing viscera, liver, and/or spleen (2).

Other less common defects are bladder extrophy and cloacal extrosphy (2, 4). These are two diagnoses within a spectrum of disease called the exstrophy-epispadias complex (EEC) in which cloacal extrophy is the most severe. Cloacal extrophy has also been referred to as the omphalocele extrophy imperforate anus spinal defects (OEIS) complex as it can be associated with spinal dysraphism (5).

Lastly, we will briefly cover a complex topic called limb-body wall complex. This is a severe pattern of fetal polymalformation defined by the presence of at least two of the following three anomalies: thoraco- or abdominoschisis, limb defects, and encephaly or encephalocele with facial defects (6).

### Pathophysiology of Abdominal Wall Defects

#### *Gastroschisis*

Gastroschisis is present in 2-5 per 10,000 live births per year worldwide (3, 7). The rate of gastroschisis is rising for unknown reasons (2). The embryological event that results in gastroschisis formation remains incompletely defined, although most believe it to be an abnormality in body wall enfolding that originates in the fourth week of development (8). A majority of prenatally diagnosed gastroschisis cases are considered simple and have a low morbidity with a high survival rate. However, approximately 11-17% of patients are categorized as complex with an associated atresia, stenosis, perforation, necrosis or volvulus. These complex patients are at greater risk of postnatal problems (9, 10). Closing, closed, or vanishing gastroschisis where the fascia constricts the bowel that is eviscerated through an abdominal wall defect resulting in intestinal stricture, atresia, necrosis or resorption is a challenging subset of complex gastroschisis (11). These cases can be associated with extreme short gut (remaining small bowel of 25cm or less) (12, 13).

### *Omphalocele*

Omphalocele, also known as exomphalos, has an incidence of 1-2.5 per 10,000 live births and is characterized by a central defect covered by a membranous sac (2, 4). Embryologically, it results from failure of midline fusion of the lateral embryologic folds with the return of the midgut into the abdomen around 10-11 weeks' gestation (2, 14). The membranous sac consists of three layers: peritoneum, Wharton's jelly, and amnion which protects the normal bowel inside (2). This anomaly is seen more commonly with advanced maternal age (2, 14). The diagnosis of omphalocele is associated with chromosomal anomalies (most commonly trisomy 13, 18, or 21) in 30% of cases and has a high risk of intrauterine fetal demise, therefore prenatal karyotype testing is advised (4, 15). It is also associated with other anomalies including cardiac, central nervous system (CNS), and Beckwith-Wiedemann syndrome (2, 14, 15). Pentalogy of Cantrell is a constellation of anomalies in which the infant has an omphalocele, sternal cleft, anterior defect in the diaphragm, absent pericardium, and ectopia cordis (2). On the other end of the spectrum, a small omphalocele that contains only midgut (no liver) and is less than 4cm in diameter is better defined as an umbilical cord hernia (2, 14).

### *Bladder/Cloacal Exstrophy*

Bladder exstrophy has an incidence of 1 in 30,000-50,000 live births while cloacal exstrophy is even more rare with an incidence of 1 in 200,000-400,000 live births(16-18). Bladder and cloacal exstrophy are theorized to result from a malformation in the normal embryogenesis of the urorectal septum within the first 2 months of gestation. The error results from the cloacal membrane undergoing apoptosis prior to complete descent of the urogenital septum (19).

### *Limb-Body Wall Complex:*

This complex is also known as body stalk anomaly, amniotic band disruption complex, and amnion rupture sequence (20, 21). The primary differentiator from other entities with abdominal wall defects is the position of the cord insertion. The defect in this complex is large, eccentric, and lateral with the abdominal organs directly attached to the placenta or the uterine wall (6). There is nearly universal early postnatal death and no current fetal intervention available (21, 22). There is an increase in maternal morbidity and adverse maternal outcomes with late diagnosis or when termination was not chosen. Those points should be discussed during counseling when the definitive diagnosis of limb-body wall complex is made (23).

## **Fetal Imaging for Abdominal Wall Defects**

### *Ultrasound*

The diagnosis and characterization of abdominal wall defects is made primarily by the use of prenatal ultrasound. Gastroschisis can be identified as early as the first trimester with exteriorized bowel without a covering. Bowel dilation is measured and reported as either intra-abdominal dilation, extra-abdominal dilation, or both. Measurements are reported as dilated if they are larger than published nomograms of bowel lumen dilation for the gestation age and these are followed throughout the pregnancy. Intra-abdominal bowel dilation is known to be associated with intestinal atresia but this can be difficult to predict prenatally (3, 24). Various

degrees of liver herniation have also been described with gastroschisis. In one report, the overall incidence was only 6% (25). Liver herniation is a risk factor for poor outcome and prenatal documentation may be helpful for prenatal counseling (25).

Omphaloceles are diagnosed via ultrasound identified in the late 1<sup>st</sup> or early 2<sup>nd</sup> trimester as prenatal ultrasound is highly sensitive in identifying the membranous sac covering an abdominal wall defect (4). Fetal echocardiogram is suggested due to associated risk of cardiac defects in up to 45% of patients (14).

Bladder exstrophy is suggested when prenatal ultrasound shows an absent bladder with normal amniotic fluid, low insertion of the umbilical cord, and bony pelvis anomaly (16). Cloacal exstrophy can be diagnosed on prenatal ultrasound with the combination of a large, midline abdominal wall defect, nonvisualization of the bladder with normal amniotic fluid, lumbosacral anomalies, and an elephant trunk like mass (pathognomonic but present in only a minority of cases) (26-28).

Limb-body wall complex is usually diagnosed with prenatal ultrasound by the end of the first trimester with the findings of major abdominal wall defect, abnormal spinal curvatures and the presence of short cord (22, 23).

#### *Fetal Magnetic Resonance Imaging (MRI)*

Fetal MRI can be used in cases of giant omphalocele, gastroschisis with liver herniation, and bladder/cloacal exstrophy to better understand the scope of the defect, to identify other anomalies, and to estimate the fetal lung volumes in order to better prognosticate postnatal outcomes (4). There is currently no role for fetal MRI in the diagnosis of gastroschisis except for in rare cases of complex gastroschisis with liver out.

Bladder exstrophy appears as an abdominal mass noted below the umbilical cord with the distal ureters appearing to end within the mass on fetal MRI (17). Cloacal exstrophy on fetal MRI has findings similar to ultrasound with absent bladder despite normal amniotic fluid, an omphalocele, protuberant anterior pelvic contour, and lack of meconium in the bowel (18, 29).

Fetal MRI has also proved to be effective in illustrating the various component of the limb-body wall complex and differentiating it from treatable abdominal wall defects. Common MRI findings are a hypoplastic thorax with multiple extruded organs attached to the placenta or the uterine wall, abnormal limb position, various degrees of thoracolumbar scoliosis/kyphoscoliosis, and a short cord (30).

#### **Fetal Surveillance and Therapy**

There is no current fetal therapy for any of the abdominal wall defects. Antenatal testing and close follow up with obstetric providers is encouraged.

### **Delivery Plan**

For fetuses diagnosed with gastroschisis, there is no evidence to support a difference in outcome between cesarean section and vaginal delivery (31). It is recommended that delivery occurs at or near to a tertiary center that is equipped with resources to manage the postnatal repair and resuscitation. This center ideally has a level III or higher NICU and available pediatric surgeon. The optimal timing of delivery is still debated in the fetal community although many of these infants are born preterm (32). Some advocate for earlier delivery as this would decrease the time that the intestine is exposed to the amniotic fluid and decrease precipitous labor at a center that is not equipped to perform postnatal resuscitation. However, early elective delivery may increase the complications due to prematurity and it is too soon to determine best timing of delivery (33). There is a multi-institutional study ongoing that is attempting to answer this question titled “Gastroschisis Outcomes of Delivery (GOOD) Study” (ClinicalTrials.gov NCT02774746).

For fetuses diagnosed with omphalocele, a cesarean section is recommended when there is liver within the sac or the defect measures >5cm in diameter (4). The argument for cesarean in these cases is to avoid rupture, dystocia, or injury to the liver. Smaller omphaloceles and umbilical cord hernias can be delivered vaginally.

### **Postnatal Management of Abdominal Wall Defects**

Infants with gastroschisis require immediate resuscitation with IV access, NG decompression, and bowel protection to prevent heat and fluid losses. Surgical options include immediate primary closure or a silo placement with plan for delayed closure. Both include inspection of the bowel and evaluation for intestinal atresia, perforation, or other complication. Primary or delayed closure may be performed with sutures or sutureless depending upon surgeon preference (34). The overall survival is greater than 90% with morbidity associated with bowel complications (atresias or perforation), prolonged TPN, prematurity issues, and short gut (35). In the rare cases of gastroschisis with liver herniation, survival falls to 43% (25). Total liver herniation is associated with the worst outcome although there are case reports of survival using various closure techniques similar to treatment of a giant omphalocele (36, 37).

Infants with omphalocele should be managed with IV hydration, maintenance of body temperature, NG placement for intestinal decompression, and ventilator support as needed (14). Surgical options include primary repair or a conservative “paint-and-wait” strategy that allows epithelialization of the sac with delayed (months to years) repair of the ventral hernia (15). Primary repair is reserved for small defects and patients without comorbid cardiac or respiratory compromise (15). Despite operative choice by the surgeon, infants should undergo postnatal evaluation for anomalies that may have been missed prenatally. It is recommended to have postnatal echocardiogram, glucose monitoring, as Beckwith-Wiedemann may present with

severe hypoglycemia, and postnatal karyotype if not completed prenatally (2). Rarely, the membranous sac covering the abdominal contents tears leading to a ruptured omphalocele. This complex problem requires urgent operative intervention to gain covering, avoid fluid loss, and prevent infectious complications (2).

Postnatal management of infants with bladder or cloacal exstrophy is complex and beyond the scope of this chapter.

### **Level of Evidence**

Grade B, Level 3a/3b (case-control studies)

## References

1. Christison-Lagay ER, Kelleher CM, Langer JC. Neonatal abdominal wall defects. *Seminars in fetal & neonatal medicine*. 2011;16(3):164-72. Epub 2011/04/09. doi: 10.1016/j.siny.2011.02.003. PubMed PMID: 21474399.
2. Kelay A, Durkin N, Davenport M. Congenital anterior abdominal defects. *Surgery (Oxford)*. 2016;34(12):621-7.
3. D'Antonio F, Virgone C, Rizzo G, Khalil A, Baud D, Cohen-Overbeek TE, Kuleva M, Salomon LJ, Flacco ME, Manzoli L, Giuliani S. Prenatal Risk Factors and Outcomes in Gastroschisis: A Meta-Analysis. *Pediatrics*. 2015;136(1):e159-69. Epub 2015/07/01. doi: 10.1542/peds.2015-0017. PubMed PMID: 26122809.
4. Lakshminarayanan B, Lakhoo K. Abdominal wall defects. *Early human development*. 2014;90(12):917-20. Epub 2014/12/03. doi: 10.1016/j.earlhumdev.2014.09.018. PubMed PMID: 25448781.
5. Koehler S, Levitt M, Calkins C. Cloacal Exstrophy. 2017. In: *Pediatric Surgery NaT* [Internet]. Online: Unbound (TM) software platform.
6. Van Allen MI, Curry C, Walden CE, Gallagher L, Patten RM. Limb-body wall complex: II. Limb and spine defects. *American journal of medical genetics*. 1987;28(3):549-65. Epub 1987/11/01. doi: 10.1002/ajmg.1320280303. PubMed PMID: 2962494.
7. Feldkamp ML, Carey JC, Sadler TW. Development of gastroschisis: review of hypotheses, a novel hypothesis, and implications for research. *American journal of medical genetics Part A*. 2007;143a(7):639-52. Epub 2007/01/19. doi: 10.1002/ajmg.a.31578. PubMed PMID: 17230493.
8. Sadler TW. The embryologic origin of ventral body wall defects. *Seminars in pediatric surgery*. 2010;19(3):209-14. Epub 2010/07/09. doi: 10.1053/j.sempedsurg.2010.03.006. PubMed PMID: 20610194.
9. Arnold MA, Chang DC, Nabaweesi R, Colombani PM, Bathurst MA, Mon KS, Hosmane S, Abdullah F. Risk stratification of 4344 patients with gastroschisis into simple and complex categories. *Journal of pediatric surgery*. 2007;42(9):1520-5. Epub 2007/09/13. doi: 10.1016/j.jpedsurg.2007.04.032. PubMed PMID: 17848242.
10. Bergholz R, Boettcher M, Reinshagen K, Wenke K. Complex gastroschisis is a different entity to simple gastroschisis affecting morbidity and mortality-a systematic review and meta-analysis. *Journal of pediatric surgery*. 2014;49(10):1527-32. Epub 2014/10/05. doi: 10.1016/j.jpedsurg.2014.08.001. PubMed PMID: 25280661.
11. Perrone EE, Olson J, Golden JM, Besner GE, Gayer CP, Islam S, Gollin G. Closing gastroschisis: The good, the bad, and the not-so ugly. *Journal of pediatric surgery*. 2018. Epub 2018/11/30. doi: 10.1016/j.jpedsurg.2018.10.033. PubMed PMID: 30482541.
12. Dennison FA. Closed gastroschisis, vanishing midgut and extreme short bowel syndrome: Case report and review of the literature. *Ultrasound (Leeds, England)*. 2016;24(3):170-4. Epub 2016/11/22. doi: 10.1177/1742271x16648360. PubMed PMID: 27867410; PMCID: PMC5105359.
13. Kimble RM, Blakelock R, Cass D. Vanishing gut in infants with gastroschisis. *Pediatric surgery international*. 1999;15(7):483-5. Epub 1999/10/20. doi: 10.1007/s003830050644. PubMed PMID: 10525904.



14. MD K. Congenital Defects of the Abdominal Wall. In: AG C, editor. Pediatric Surgery. 7th Edition ed. Philadelphia, PA: Elsevier; 2006. p. 973-84.
15. Islam S. Advances in surgery for abdominal wall defects: gastroschisis and omphalocele. *Clinics in perinatology*. 2012;39(2):375-86. Epub 2012/06/12. doi: 10.1016/j.clp.2012.04.008. PubMed PMID: 22682386.
16. Goyal A, Fishwick J, Hurrell R, Cervellione RM, Dickson AP. Antenatal diagnosis of bladder/cloacal exstrophy: challenges and possible solutions. *Journal of pediatric urology*. 2012;8(2):140-4. Epub 2011/06/07. doi: 10.1016/j.jpuro.2011.05.003. PubMed PMID: 21641871.
17. Goldman S, Szejnfeld PO, Rondon A, Francisco VV, Bacelar H, Leslie B, Barroso U, Jr., Ortiz V, Macedo A, Jr. Prenatal diagnosis of bladder exstrophy by fetal MRI. *Journal of pediatric urology*. 2013;9(1):3-6. Epub 2012/07/31. doi: 10.1016/j.jpuro.2012.06.018. PubMed PMID: 22841402.
18. Calvo-Garcia MA, Kline-Fath BM, Rubio EI, Merrow AC, Guimaraes CV, Lim FY. Fetal MRI of cloacal exstrophy. *Pediatric radiology*. 2013;43(5):593-604. Epub 2012/11/28. doi: 10.1007/s00247-012-2571-3. PubMed PMID: 23184094.
19. van der Putte SC, Spliet WG, Nikkels PG. Common ("classical") and covered cloacal exstrophy: a histopathological study and a reconstruction of the pathogenesis. *Pediatric and developmental pathology : the official journal of the Society for Pediatric Pathology and the Paediatric Pathology Society*. 2008;11(6):430-42. Epub 2007/12/15. doi: 10.2350/07-06-0292.1. PubMed PMID: 18078363.
20. Kalousek DK, Bamforth S. Amnion rupture sequence in previable fetuses. *American journal of medical genetics*. 1988;31(1):63-73. Epub 1988/09/01. doi: 10.1002/ajmg.1320310110. PubMed PMID: 3223500.
21. Smrcek JM, Germer U, Krokowski M, Berg C, Krapp M, Geipel A, Gembruch U. Prenatal ultrasound diagnosis and management of body stalk anomaly: analysis of nine singleton and two multiple pregnancies. *Ultrasound in obstetrics & gynecology : the official journal of the International Society of Ultrasound in Obstetrics and Gynecology*. 2003;21(4):322-8. Epub 2003/04/22. doi: 10.1002/uog.84. PubMed PMID: 12704737.
22. Daskalakis G, Sebire NJ, Jurkovic D, Sniijders RJ, Nicolaidis KH. Body stalk anomaly at 10-14 weeks of gestation. *Ultrasound in obstetrics & gynecology : the official journal of the International Society of Ultrasound in Obstetrics and Gynecology*. 1997;10(6):416-8. Epub 1998/02/26. doi: 10.1046/j.1469-0705.1997.10060416.x. PubMed PMID: 9476328.
23. Costa ML, Couto E, Furlan E, Zaccaria R, Andrade K, Barini R, Nomura ML. Body stalk anomaly: adverse maternal outcomes in a series of 21 cases. *Prenatal diagnosis*. 2012;32(3):264-7. Epub 2012/03/21. doi: 10.1002/pd.2947. PubMed PMID: 22430725.
24. Nick AM, Bruner JP, Moses R, Yang EY, Scott TA. Second-trimester intra-abdominal bowel dilation in fetuses with gastroschisis predicts neonatal bowel atresia. *Ultrasound in obstetrics & gynecology : the official journal of the International Society of Ultrasound in Obstetrics and Gynecology*. 2006;28(6):821-5. Epub 2006/10/10. doi: 10.1002/uog.2858. PubMed PMID: 17029299.
25. McClellan EB, Shew SB, Lee SS, Dunn JC, Deugarte DA. Liver herniation in gastroschisis: incidence and prognosis. *Journal of pediatric surgery*. 2011;46(11):2115-8. Epub 2011/11/15. doi: 10.1016/j.jpedsurg.2011.07.010. PubMed PMID: 22075341.

26. Hamada H, Takano K, Shiina H, Sakai T, Sohda S, Kubo T. New ultrasonographic criterion for the prenatal diagnosis of cloacal exstrophy: elephant trunk-like image. *The Journal of urology*. 1999;162(6):2123-4. Epub 1999/11/24. PubMed PMID: 10569600.
27. Bischoff A, Calvo-Garcia MA, Baregamian N, Levitt MA, Lim FY, Hall J, Pena A. Prenatal counseling for cloaca and cloacal exstrophy-challenges faced by pediatric surgeons. *Pediatric surgery international*. 2012;28(8):781-8. Epub 2012/08/11. doi: 10.1007/s00383-012-3133-3. PubMed PMID: 22878705; PMCID: PMC3417092.
28. Austin PF, Homsy YL, Gearhart JP, Porter K, Guidi C, Madsen K, Maizels M. The prenatal diagnosis of cloacal exstrophy. *The Journal of urology*. 1998;160(3 Pt 2):1179-81. Epub 1998/08/27. PubMed PMID: 9719304.
29. Clements MB, Chalmers DJ, Meyers ML, Vemulakonda VM. Prenatal diagnosis of cloacal exstrophy: a case report and review of the literature. *Urology*. 2014;83(5):1162-4. Epub 2014/01/08. doi: 10.1016/j.urology.2013.10.050. PubMed PMID: 24393699.
30. Aguirre-Pascual E, Epelman M, Johnson AM, Chauvin NA, Coleman BG, Victoria T. Prenatal MRI evaluation of limb-body wall complex. *Pediatric radiology*. 2014;44(11):1412-20. Epub 2014/06/15. doi: 10.1007/s00247-014-3026-9. PubMed PMID: 24928524.
31. Kirolos DW, Abdel-Latif ME. Mode of delivery and outcomes of infants with gastroschisis: a meta-analysis of observational studies. *Archives of disease in childhood Fetal and neonatal edition*. 2018;103(4):F355-f63. Epub 2017/10/04. doi: 10.1136/archdischild-2016-312394. PubMed PMID: 28970315.
32. Friedman AM, Ananth CV, Siddiq Z, D'Alton ME, Wright JD. Gastroschisis: epidemiology and mode of delivery, 2005-2013. *American journal of obstetrics and gynecology*. 2016;215(3):348.e1-9. Epub 2016/03/31. doi: 10.1016/j.ajog.2016.03.039. PubMed PMID: 27026476; PMCID: PMC5003749.
33. Landisch RM, Yin Z, Christensen M, Szabo A, Wagner AJ. Outcomes of gastroschisis early delivery: A systematic review and meta-analysis. *Journal of pediatric surgery*. 2017;52(12):1962-71. Epub 2017/09/28. doi: 10.1016/j.jpedsurg.2017.08.068. PubMed PMID: 28947324.
34. Riboh J, Abrajano CT, Garber K, Hartman G, Butler MA, Albanese CT, Sylvester KG, Dutta S. Outcomes of sutureless gastroschisis closure. *Journal of pediatric surgery*. 2009;44(10):1947-51. Epub 2009/10/27. doi: 10.1016/j.jpedsurg.2009.03.027. PubMed PMID: 19853753.
35. Suominen J, Rintala R. Medium and long-term outcomes of gastroschisis. *Seminars in pediatric surgery*. 2018;27(5):327-9. Epub 2018/11/11. doi: 10.1053/j.sempedsurg.2018.08.008. PubMed PMID: 30413265.
36. Morris MW, Jr., Westmoreland T, Sawaya DE, Blewett CJ. Staged closure with negative pressure wound therapy for gastroschisis with liver herniation: a case report. *Journal of pediatric surgery*. 2013;48(5):E13-5. Epub 2013/05/25. doi: 10.1016/j.jpedsurg.2013.03.005. PubMed PMID: 23701801.
37. Svetanoff WJ, Zendejas B, Demehri FR, Cuenca A, Nath B, Smithers CJ. Giant Gastroschisis with Complete Liver Herniation: A Case Report of Two Patients. *Case reports in surgery*. 2019;2019:4136214. Epub 2019/02/19. doi: 10.1155/2019/4136214. PubMed PMID: 30775044; PMCID: PMC6350565.

## Intestinal Obstructions, Atresias and Abdominal Cysts

Niti Shahi, David Stitelman, Tracy Grikscheit, and Ahmed I. Marwan

### Introduction

Diagnosed on prenatal imaging, dilated bowel, polyhydramnios, and abdominal cysts and masses are frequent referrals to a pediatric surgeon. Bowel dilation with or without polyhydramnios can be signs of intestinal obstruction, defined as interruption of the passage of gastrointestinal contents distally.

### Types of Intestinal Obstruction

1. **Proximal obstruction** (esophagus, proximal small bowel)
  - a. Fetus cannot swallow amniotic fluid which leads to **polyhydramnios**
  - b. The higher the obstruction, the more severe the polyhydramnios
  - c. Examples: Esophageal atresia, duodenal web, duodenal atresia, annular pancreas, and malrotation with volvulus
  
2. **Distal obstruction** (mid- to distal small bowel, colon)
  - a. Normal amniotic fluid volume
  - b. Distended intestinal loops on ultrasound which leads to **dilated bowel**
  - c. Examples: Intestinal atresia (Jejunal/ileal atresia, colon atresia), Meconium plug, Neonatal small left colon syndrome, Hirschsprung's disease, Meconium ileus, Anorectal malformation, Cloaca with hydrocolpos, and extrinsic compression from masses or cysts

### 1. Proximal: Polyhydramnios

#### **Duodenal Web/ Duodenal Atresia / Annular Pancreas**

**Duodenal web:** Duodenal webs are a rare congenital abnormality, ranging from 1:10,000 to 1:40,000) defined by the presence of a “web” composed of mucosa and submucosa (1, 2). Similar to duodenal atresias, the formation of duodenal webs is believed to be secondary to incomplete canalization of the duodenal lumen during embryologic development (1). The presentation of duodenal webs is often during infancy with the onset of symptoms associated with a “high” (2, 3). Duodenal webs are diagnosed on upper GI series and, less frequently, upper endoscopy (4). A wide range of treatments has been described for this rare anomaly ranging from endoscopic balloon dilation to operative repair with duodenoplasty, duodenoduodenostomy, web resection, and/or duodenojejunostomy (4, 5).

**Duodenal atresia:** Duodenal atresia is the most common type of intestinal atresia and is thought

to arise secondary to a failure of the duodenum to re-canalize during the first trimester (6). Although it is the most common type of intestinal atresia, duodenal atresia is rare with an incidence of 1:5000 to 1: 10,000 (7, 8). Up to 30% of patients with duodenal atresia have trisomy 21 (9). Compared to jejunal and ileal atresias, duodenal atresias also have a higher rate of associated malformations (e.g. cardiac malformations). Therefore prior to operative management (typically a duodenoduodenostomy), patients should be worked up for cardiovascular anomalies with an echocardiogram (10). When duodenal atresia is suspected in-utero, karyotyping for Trisomy 21 should be offered. Other conditions that are associated with Trisomy 21 include: duodenal web, annular pancreas, anorectal malformation, esophageal atresia, and Hirschsprung's disease (11).

**Malrotation with midgut volvulus:** Malrotation with midgut volvulus occurs secondary to an aberration from the normal process of counter-clockwise intestinal rotation and attachment during the fifth gestational week (12, 13). Abnormal attachments, known as Ladd's bands, can cause compression of adjacent bowel (12). Malrotation can be further categorized by the presence of rotation proximal or distal to the superior mesenteric artery as pre-arterial and post-arterial malrotation. In the prenatal setting, a fetal midgut volvulus can manifest as an intestinal atresia with extensive bowel necrosis.

**Esophageal atresia:** Esophageal atresia is a congenital anomaly that occurs in 1:2500 infants (14). The etiology of esophageal atresia is largely unknown (15). Infants with esophageal atresia have an increased incidence of VACTERL and require a work-up including chest x-ray, echocardiogram (to assess the aortic arch and any cardiac anomalies), renal ultrasound, and sacral ultrasound (15). Prenatally, they are associated with an absent stomach and occasionally a dilated esophagus.

## 2. Distal: Dilated bowel

### Intestinal Atresia

**Jejunoileal atresias (prenatal):** Following duodenal atresias, jejunal and ileal atresias are the second most common type of intestinal atresias. The cause of jejunoileal atresias is believed to be late intrauterine vascular accidents (9). Risk factors for the development of jejunoileal atresias include gastroschisis, cystic fibrosis, vasoconstrictive medications, and smoking during the first trimester of pregnancy (10).

Types of intestinal atresias (28):

<b>Type 1</b>	obstructing membrane
<b>Type 2</b>	replacement of intestinal tissue with a cord

<b>Type 3a</b>	2 blind ends of intestine, separated by mesenteric defect
<b>Type 3b</b>	apple-peel deformity
<b>Type 4</b>	multiple intestinal atresias

**Colonic atresias:** Colonic atresias are extremely rare with an incidence of less than 1 in 20,000 (16, 17). The cause of colonic atresia warrants further exploration but may also be secondary to intravascular accidents in-utero. Patients with colonic atresia need an evaluation for Hirschsprung's disease and for additional concomitant intestinal atresias (16, 18).

### **Meconium Plug/Meconium Ileus/Small left Colon/ Hirschsprung's**

**Meconium plug:** **Meconium plugs** can be defined as an obstruction secondary to inspissated meconium in the colon and should be suspected in patients who fail to pass the meconium in the first 24 to 48 hours, with an increased incidence in low birth neonates (19). Hirschsprung's disease should be considered in patients with meconium plugs, as up to 38 percent of cases have a concomitant diagnosis (20). Compared to meconium ileus, meconium plugs are considered to be a more benign condition and are often diagnosed and treated postnatally with contrast low-osmolality enemas; additionally, saline or glycerin enemas can also be used for treatment of meconium plugs (19).

**Meconium ileus:** In contrast, **meconium ileus** is an obstruction due to meconium in the small bowel, specifically extending into the terminal ileum. Generally, meconium ileus can be categorized into simple and complex; complex meconium ileus is associated with gastrointestinal complications including bowel obstruction, volvulus, meconium peritonitis, and perforation in up to 50% of patients (21, 22). Unlike meconium plug syndrome, meconium ileus has a higher degree of association with cystic fibrosis. Meconium ileus, like meconium plug syndrome, should be suspected in infants who fail to pass meconium in the first 48 hours of life. Premature infants, especially those born at 25 to 27 weeks, have a higher likelihood of failing to pass meconium within the first 48 hours. Associated with meconium obstruction, **meconium pseudocysts** consist of a thinned-out wall continuous with the intestinal wall lacking a layer of epithelium (23). Meconium pseudocysts should be differentiated from cystic meconium peritonitis which stems from cyst formation after peritonitis and fibrosis of adjacent bowel (23). A feared complication of meconium obstruction is **meconium peritonitis**, a sterile chemical peritonitis secondary to small bowel perforation in-utero (24, 25). Thus, intra-abdominal calcifications develop, which may be apparent on prenatal ultrasonography or MRI.

**Management of Meconium ileus:** In cases where meconium ileus is suspected prenatally, paternal CFTR testing is recommended (22). If the CFTR test demonstrates a mutation, amniocentesis should be considered (22). In addition to CFTR testing and possible

amniocentesis, repeat ultrasounds should be conducted. One of the challenges of ultrasound is that hyperechoic masses can be normal in the 2nd and 3rd trimesters of pregnancy (22).

**Neonatal Small Left Colon Syndrome:** Neonatal small left colon syndrome is characterized by a narrow left colon; the etiology is poorly understood, but there is an association with maternal diabetes (26, 27).

**Hirschsprung's disease:** Hirschsprung's disease develops in 1 in 6000 infants as a result of lack of enteric ganglion cells in the distal bowel (22, 28, 29). Subsequently, infants can have symptoms of constipation, obstruction, and enterocolitis. A more severe variant of Hirschsprung's disease, total colonic aganglionosis, involves the paucity of ganglion cells extending to the small intestine (29).

**Management of Meconium plugs, Neonatal Small Left Colon Syndrome, and Hirschsprung's disease:** A rectal suction biopsy is recommended in these patients to evaluate for the presence of ganglion cells.

#### **Anorectal malformations/MMIHS/Intestinal Duplications:**

**Anorectal malformation:** Anorectal malformations are rare anomalies that present in 1 in 5000 patients (30). They span a variety of defects including cloacae, recto-bladder neck fistulae, recto-vestibular fistulae, recto-urethral bulbar fistulae, recto-urethral prostatic fistulae, anorectal malformations without fistulas, and rectal atresias (31, 32).. In the study by Cass et al, the most significant cause of mortality for infants with anorectal malformations were concurrent congenital anomalies (i.e. VACTERL) leading to organ failure (7). VACTERL workup is required for these patients.

**Megacystis-Microcolon-Intestinal Hypoperistalsis Syndrome (MMIHS):** MMIHS is a rare autosomal recessive syndrome, resulting in functional obstruction in neonates (8, 22). The cause of MMIHS is believed to be a mutation of gamma smooth level actin, specifically ACTG2; thus, patients develop bowel and bladder distention and a microcolon (33). Complications include a high mortality in infants and volvulus.

**Intestinal duplications:** Intestinal duplications can present as cystic or tubular structures at any point along the gastrointestinal tract on the mesenteric side (34). The cause of intestinal duplications is not fully understood but they are thought to arise within the first 4-8 weeks of embryological development (35). Accepted features of intestinal duplications include continuity with the intestinal tract and a two-layer lining with mucosa and or epithelium (34, 36). The most common location of intestinal duplications is the ileum (34). The duplication may contain gastric tissue which can increase the risk of ulcer formation and gastrointestinal bleeding (34). Due to the malignant potential, postnatal segmental resection of the associated bowel and the duplication is often recommended (18).

### **3. Cysts**

***Ovarian and Retroperitoneal Cysts/Masses:*** Please refer to chapter 5 “Fetal Masses and Neoplasms” for review.

***Choledochal cysts, liver cysts, and cystic biliary atresia:*** Choledochal cysts, liver cysts, and cystic biliary atresia are difficult to distinguish from other intra-abdominal cysts on prenatal imaging (37). Given the rarity of diagnoses of hepatobiliary cysts on prenatal imaging, there are sparse recommendations for management and the incidence is relatively unknown (37). In a systematic review by Leombroni et al, a majority (60%) of hepatic cysts regressed over the course of pregnancy or after birth while biliary cysts were more likely to increase in size. As a result, many biliary cysts become symptomatic with presentation including features of biliary obstruction (37). Hepatobiliary cysts should be carefully differentiated with attention to biliary atresia. The gallbladder should be evaluated on ultrasonography. Further imaging such as MRI may be helpful to differentiate between hepatic and biliary cysts and biliary atresia (37). Cystic biliary atresia is a rare variant of biliary atresia with cystic degeneration and obliteration of the bile ducts. The management of cystic biliary atresia often involves the Kasai procedure and a potential liver transplant (38).

***Mesenteric cysts:*** Mesenteric cysts are congenital lesions most frequently found in the small bowel mesentery (36). A majority of these lesions present prenatally or in early childhood (39). On imaging, they manifest as anechoic cysts (40, 41). Clinically, symptomatic patients present with obstruction, which can progress to volvulus (39). Patients with mesenteric cysts are treated surgically with complete resection of the cyst and associated bowel (if a common wall of cyst and bowel is involved) (39, 42, 43).

***Lymphatic malformation:*** Lymphatic malformations are cystic structures that can occur in the abdomen and are potential etiologies of obstruction (36).

***Omental cysts:*** Omental cysts are an extremely uncommon type of intra-abdominal cyst that can arise from obstruction of lymphatics and/or aberrant lymphatic tissue (44). In contrast to mesenteric cysts, omental cysts are larger and are located closer to the abdominal wall (35).

#### **Management of Intra-abdominal cysts:**

Intra-abdominal cysts can be monitored carefully for size and changes in appearance with ultrasonography. In most cases, management of the cysts can wait until after delivery. The most common intra-abdominal cyst, an ovarian cyst, typically regresses postnatally from decreased hormone stimulation. In contrast to ovarian cysts which regress, other types of intra-abdominal cysts show a different progression in utero. For example, choledochal cysts increase in size over the course of pregnancy and intestinal duplication often has no change in size (36).

## **Fetal Imaging**

### ***Ultrasound:***

The mainstay of diagnosis of prenatal abdominal anomalies is ultrasonography, specifically at 18 to 24 weeks. In these patients, close attention is paid to the echogenicity of the bowel. Echogenic bowel is the bright appearance of bowel or bowel wall on ultrasound, typically identified in 2<sup>nd</sup> or 3<sup>rd</sup> trimester of pregnancy (45). Generally, bowel echogenicity can be indicative of a wide range of pathologies including meconium ileus (cystic fibrosis), congenital infections (i.e. CMV, parvovirus), selective intrauterine growth restriction (sIUGR), intra-amniotic bleeding, placental abnormalities (i.e. cord strangulation, toxemia) intestinal obstruction, and normal variants (i.e. swallowed blood after amniocentesis). Most often, echogenic bowel is idiopathic. The significance of echogenic bowel is unclear, but it is an indication for further testing including infectious screen and/or amniocentesis. Bowel echogenicity associated with maternal bleeding is associated with a poor pregnancy outcome. On the contrary, echogenicity associated with intestinal obstruction typically has a good prognosis but requires postnatal surgical intervention.

Another critical finding of the prenatal ultrasound is the presence of polyhydramnios or oligohydramnios. Increased amniotic fluid depth is measured in the deepest fluid pocket on ultrasound (46). Polyhydramnios can be caused by reduced swallowing of amniotic fluid by the fetus in the setting of high intestinal obstruction (47).

Patients with evidence of prenatal bowel obstruction may demonstrate evidence of proximal bowel dilation on ultrasound, with an intestinal width greater than 7 mm wide (48). Bowel obstruction in fetuses and infants can be further categorized into high (proximal) and low (distal) obstruction. As described above, high obstruction includes esophageal and duodenal atresia, and generally, patients with higher obstruction have more severe polyhydramnios. In contrast, low obstruction involves an obstruction in the mid or distal small bowel or colon. Unlike high bowel obstructions, low obstruction typically demonstrates normal amniotic fluid volume on ultrasonography.

Similarly, in the rare case of prenatal segmental volvulus, there may be dilated proximal loops of fluid filled bowel and/or a whirlpool sign. While causes of intestinal obstruction are less likely to resolve without intervention, asymptomatic prenatal segmental volvulus may resolve on its own and can be monitored with weekly sonography (49).

### ***MRI:***

MRI can be used as a supplementary tool for further work-up of a suspected anomaly after ultrasonography. In the literature, MRI is recommended for additional assessment after 17 weeks of gestation due to the risk of disruption of the major cellular development and organogenesis if done in the first trimester (50, 51). The primary benefit for prenatal MRI currently is for the evaluation of neurologic defects (52). However, MRI can also be considered for use in patients with atresias, abdominal masses, and abdominal wall defects (52). Compared to ultrasound, MRI is better at differentiating dilated bowel from intra-abdominal cysts and identifying the characteristics of the cysts (36, 51). However, MRI does have its limitations including its high cost



and impaired visualization in polyhydramnios and should be reserved for select cases.

***Echocardiogram:***

Prenatal echocardiogram should be conducted in patients with VACTERL abnormalities and a high risk for cardiovascular anomalies (such as duodenal atresia) (53). If congenital heart disease is diagnosed, serial echocardiograms may be warranted (53).

**Level of Evidence**

Grade C, Level 4 (Case series)

### References

1. Beeks A, Gosche J, Giles H, Nowicki M. Endoscopic dilation and partial resection of a duodenal web in an infant. *J Pediatr Gastroenterol Nutr.* 2009;48(3):378-81.
2. Eksarko P, Nazir S, Kessler E, LeBlanc P, Zeidman M, Asarian AP, et al. Duodenal web associated with malrotation and review of literature. *Journal of surgical case reports.* 2013;2013(12).
3. Tzeng GY, Lin CC, Chen HC, Peng HC, Chang WT, Chi CS. Congenital duodenal web in late infancy and childhood: a report of two cases. *Zhonghua Yi Xue Za Zhi (Taipei).* 1994 May;53(5):307-10.
4. Rattan KN, Singh J, Dalal P. Delayed presentation of congenital intrinsic duodenal obstruction in children with non-bilious vomiting: a diagnostic dilemma. *Journal of Pediatric and Neonatal Individualized Medicine (JPNIM).* 2018;7(2):e070218.
5. Muensterer OJ, Hansen EN. Resection of a duodenal web using single-incision pediatric endosurgery. *J Pediatr Surg.* 2011;46(5):989-93.
6. Ando H, Kaneko K, Ito F, Seo T, Harada T, Watanabe Y. Embryogenesis of pancreaticobiliary maljunction inferred from development of duodenal atresia. *J Hepatobiliary Pancreat.* 1999;6(1):50-4.
7. Lau PE, Cruz S, Cassady CI, Mehollin-Ray AR, Ruano R, Keswani S, et al. Prenatal diagnosis and outcome of fetal gastrointestinal obstruction. *J Pediatr Surg.* 2017;52(5):722-5.
8. Puri P. Megacystis-microcolon-intestinal hypoperistalsis syndrome. . *Hirschsprung's disease and allied disorders.* 2008.:267,267-273.
9. Best KE, Tennant PW, Addor MC, Bianchi F, Boyd P, Calzolari E, et al. Epidemiology of small intestinal atresia in Europe: a register-based study. *Arch Dis Child Fetal Neonatal Ed.* 2012 Sep;97(5):F353-8.
10. Sweeney B, Surana R, Puri P. Jejunoileal atresia and associated malformations: correlation with the timing of in utero insult. *J Pediatr Surg.* 2001;36(5):774-6.
11. Stoll C, Dott B, Alembik Y, Roth M. Associated congenital anomalies among cases with Down syndrome. *European journal of medical genetics.* 2015;58(12):674-80.
12. Lampl B, Levin TL, Berdon WE, Cowles RA. Malrotation and midgut volvulus: a historical review and current controversies in diagnosis and management. *Pediatr Radiol.* 2009;39(4):359-66.
13. Stanfill AB, Pearl RH, Kalvakuri K, Wallace LJ, Vegunta RK. Laparoscopic Ladd's procedure: treatment of choice for midgut malrotation in infants and children. *Journal of laparoendoscopic & advanced surgical techniques.* 2010;20(4):369-72.
14. Spitz L. Esophageal atresia: lessons I have learned in a 40-year experience. . *Journal of pediatric surgery.* 2006.;41(10):1635,1635-1640.
15. Pfendner EG, Lucky AW. Epidermolysis Bullosa with Pyloric Atresia. In: Adam MP, Ardinger HH, Pagon RA, Wallace SE, Bean LJH, Stephens K, et al, editors. *GeneReviews*((R)). Seattle (WA): University of Washington, Seattle. *GeneReviews* is a registered trademark of the University of Washington, Seattle. All rights reserved; 1993.
16. Jessula S, Van Den Hof M, Mateos-Corral D, Mills J, Davies D, Romao R. Predictors for Surgical Intervention and Surgical Outcomes in Neonates with Cystic Fibrosis. *J Pediatr Surg.*

2018.

17. Karnak I, Ciftci AO, Şenocak ME, Tanyel FC, Büyükpamukçu N. Colonic atresia: surgical management and outcome. *Pediatric surgery international*. 2001.;17(8):631,631-635.
18. Hajivassiliou C. Intestinal obstruction in neonatal/pediatric surgery. *Seminars in pediatric surgery*; Elsevier; 2003.
19. Kubota A, Shiraishi J, Kawahara H, Okuyama H, Yoneda A, Nakai H, et al. Meconium-related ileus in extremely low-birthweight neonates: Etiological considerations from histology and radiology. *Pediatrics International*. 2011;53(6):887-91.
20. Buonpane C, Lautz TB, Hu Y. Should we look for Hirschsprung disease in all children with meconium plug syndrome? *J Pediatr Surg*. 2019.
21. Saleh N, Geipel A, Gembruch U, Heep A, Heydweiller A, Bartmann P, et al. Prenatal diagnosis and postnatal management of meconium peritonitis. *J Perinat Med*. 2009;37(5):535-8.
22. Jerdee T, Newman B, Rubesova E. Meconium in perinatal imaging: associations and clinical significance. *Seminars in Ultrasound, CT and MRI*; Elsevier; 2015.
23. Minato M, Okada T, Miyagi H, Honda S, Takazawa K, Kubota KC, et al. Meconium pseudocyst with particular pathologic findings: a case report and review of the literature. *J Pediatr Surg*. 2012;47(4):e9-e12.
24. Kamata S, Nose K, Ishikawa S, Usui N, Sawai T, Kitayama Y, et al. Meconium peritonitis in utero. *Pediatr Surg Int*. 2000;16(5-6):377-9.
25. Chan K, Tang M, Tse H, Tang R, Tam P. Meconium peritonitis: prenatal diagnosis, postnatal management and outcome. *Prenat Diagn*. 2005;25(8):676-82.
26. Wood K, Jinadatha A, Agrawal K, Narayanan S. Neonatal small left colon syndrome (NSLCS): Rare but important complication in an infant of diabetic mother. *BMJ Case Rep*. 2018 Jan 6;2018:10.1136/bcr,2017-223456.
27. Ellis H, Kumar R, Kostyrka B. Neonatal small left colon syndrome in the offspring of diabetic mothers—an analysis of 105 children. *J Pediatr Surg*. 2009;44(12):2343-6.
28. Pathak M, Saxena R, Sinha A, Singh V,. Hirschsprung's disease and neonatal intestinal obstruction: Where does it lie in the spectrum? *Journal of Clinical Neonatology*. 2018(7(4)):231.
29. Kenny SE, Tam PK, Garcia-Barcelo M,. Hirschsprung's disease. *Seminars in pediatric surgery*. 2010;19(3):194,194-200.
30. Wetherill C, Sutcliffe J. Hirschsprung disease and anorectal malformation. *Early Hum Dev*. 2014;90(12):927-32.
31. Bischoff A, Levitt MA, Peña A. Update on the management of anorectal malformations. *Pediatr Surg Int*. 2013;29(9):899-904.
32. Bischoff A, Martinez-Leo B, Peña A. Laparoscopic approach in the management of anorectal malformations. *Pediatr Surg Int*. 2015;31(5):431-7.
33. Tuzovic L, Tang S, Miller RS, Rohena L, Shahmirzadi L, Gonzalez K, et al. New Insights into the Genetics of Fetal Megacystis: ACTG2 Mutations, Encoding gamma-2 Smooth Muscle Actin in Megacystis Microcolon Intestinal Hypoperistalsis Syndrome (Berdon Syndrome). *Fetal Diagn Ther*. 2015;38(4):296-306.
34. Brown RL, Azizkhan RG. *Seminars in Pediatric surgery*. 1999;8(4):202,202-209.
35. Fahy AS, Pierro A. A Systematic Review of Prenatally Diagnosed Intra-abdominal Enteric Duplication Cysts. *European Journal of Pediatric Surgery*. 2018.

36. Tu C. Ultrasound and differential diagnosis of fetal abdominal cysts. *Experimental and therapeutic medicine*. 2017;13(1):302-6.
37. Leombroni M, Buca D, Celentano C, Liberati M, Bascietto F, Gustapane S, et al. Outcomes associated with fetal hepatobiliary cysts: systematic review and meta-analysis. *Ultrasound in Obstetrics & Gynecology*. 2017;50(2):167-74.
38. Lobeck IN, Sheridan R, Lovell M, Dupree P, Tiao GM, Bove KE. Cystic biliary atresia and choledochal cysts are distinct histopathologic entities. *Am J Surg Pathol*. 2017;41(3):354-64.
39. Chang TS, Ricketts R, Abramowksy CR, Cotter BD, Steelman CK, Husain A, et al. Mesenteric cystic masses: a series of 21 pediatric cases and review of the literature. *Fetal and pediatric pathology*. 2011;30(1):40-4.
40. Gupta P, Sharma R, Kumar S, Gadodia A, Roy K, Malhotra N, et al. Role of MRI in fetal abdominal cystic masses detected on prenatal sonography. *Arch Gynecol Obstet*. 2010;281(3):519-26.
41. Santo S, Marques JP, Veca P, Melo A, Da Graca LM. Prenatal ultrasonographic diagnosis of abdominal cystic lymphangioma: A case report. *The Journal of Maternal-Fetal & Neonatal Medicine*. 2008;21(8):565-6.
42. Wootton-Gorges SL, Thomas KB, Harned RK, Wu SR, Stein-Wexler R, Strain JD. Giant cystic abdominal masses in children. *Pediatr Radiol*. 2005;35(12):1277-88.
43. Nam SH, Kim DY, Kim SC, Kim IK. The surgical experience for retroperitoneal, mesenteric and omental cyst in children. *Journal of the Korean Surgical Society*. 2012;83(2):102-6.
44. DeRusso PA, Benson J, Lau H. Intestinal malrotation and omental cyst presenting as fetal ascites. *J Pediatr Gastroenterol Nutr*. 2003;36(2):283-6.
45. St-Vil D, Brandt ML, Panic S, Bensoussan A, Blanchard H. Meckel's diverticulum in children: a 20-year review. *J Pediatr Surg*. 1991;26(11):1289-92.
46. Kouamé N, N'goan-Domoua A, Nikiéma Z, Konan A, N'guessan K, Sétchéou A, et al. Polyhydramnios: A warning sign in the prenatal ultrasound diagnosis of foetal malformation? *Diagnostic and interventional imaging*. 2013;94(4):433-7.
47. Kim JY, You JY, Chang KH, Choi S, Oh S, Seo J, et al. Association Between Prenatal Sonographic Findings of Duodenal Obstruction and Adverse Outcomes. *Journal of Ultrasound in Medicine*. 2016;35(9):1931-8.
48. Goruppi I, Arévalo S, Gander R, Molino J, Oria M, Carreras E, et al. Role of intraluminal bowel echogenicity on prenatal ultrasounds to determine the anatomical level of intestinal atresia. *The Journal of Maternal-Fetal & Neonatal Medicine*. 2017;30(1):103-8.
49. Bartholmot C, Faure J, Grosjean F, Couture A, Forgues D, Fuchs F, et al. Prenatal diagnosis of antenatal midgut volvulus: Specific ultrasound features. *Prenat Diagn*. 2019;39(1):16-25.
50. Mervak BM, Altun E, McGinty KA, Hyslop WB, Semelka RC, Burke LM. MRI in pregnancy: Indications and practical considerations. *Journal of Magnetic Resonance Imaging*. 2019.
51. Saleem SN. Fetal MRI: An approach to practice: A review. *Journal of advanced research*. 2014;5(5):507-23.
52. Pugash D, Brugger PC, Bettelheim D, Prayer D. Prenatal ultrasound and fetal MRI: the comparative value of each modality in prenatal diagnosis. *Eur J Radiol*. 2008;68(2):214-26.
53. Donofrio MT, Moon-Grady AJ, Hornberger LK, Copel JA, Sklansky MS, Abuhamad A, et al. Diagnosis and treatment of fetal cardiac disease: a scientific statement from the American Heart Association. *Circulation*. 2014;129(21):2183-242.

## **Multiple Gestation, Twin-Twin Transfusion Syndrome (TTTS) and Twin Reversed Arterial Perfusion (TRAP) Sequence**

**Rony Marwan, Brad Feltis, William Block, and Micheal Zaretsky**

### **Introduction**

In the United States, there has been a steady increase in the number of twin pregnancies over the past few decades. From 1980 to 2009 rates increased 76 percent for women aged 30-34, nearly 100 percent for women aged 35-39, and more than 200 percent for women 40 and older. Historically twinning rates peak at age 35-39 and decline thereafter, however since 1997 the rates are highest among women in their 40s. In fact 7 percent of all births to women older than 40 were the result of a twin delivery [1].

The rate of spontaneous twinning increases with maternal age and the percentage of women above the age of 30 and older increased from 20 percent in 1980 to more than 35 percent for 2000-2009. Maternal age accounts for approximately one-third of the increase in twinning rates. Assisted reproductive technologies (ART) are more common in the greater than 30 age range and accounts for about two-thirds the increase in twinning [1].

If rates remained similar to the 1980's nearly a million fewer twins would have been delivered. The health care implications are significant as one-half of twins are low birth weight and 1 in 10 are very low birth weight [1]. Greater than a quarter of very low-birth weight infants (< 1500 gms) born in the United States are derived from twins and higher order gestation and they account for one of every seven infants who die [2].

There are substantial maternal risks as well with two-fold increase risks of preeclampsia, postpartum hemorrhage and maternal deaths when compared to their singleton co-horts. Not surprisingly, these risks correlate with increasing fetal number [3].

### **Chorionicity**

Of paramount importance in the evaluation of twins and higher order gestation is the evaluation and determination of chorionicity, the number of placentas and amniotic sacs present on ultrasound. The difference in risk assessment between dichorionic (separate placenta and, therefore, separate sacs) and monochorionic (a single placenta where twins can have one sac, termed monoamniotic, or two sacs, termed diamniotic) gestation is significant. Perinatal morbidity, mortality and neurological sequelae are significantly higher in the setting of monochorionicity. Determination of zygosity is less important as outcomes of monozygotic twin gestation with dichorionic placentation are no different than those of dizygotic twins [4]. The frequency of spontaneous monozygotic twinning is thought to be static with a rate of 1/250 worldwide. There is, however, a higher rate of monozygotic twinning secondary to assisted reproductive technologies (ART). This may be secondary to minor trauma to the blastocyst during

ART. One study determined the rate of monochorionicity to be 3.2 percent compared to background rate of 0.4 percent [5].

Spontaneous abortion is more common with twin gestation with a significantly increased incidence in monochorionic twins versus dichorionic twins at a 18:1 ratio. Fetal malformations are also significantly increased in twin gestation versus singletons. Major malformations and minor malformations are found in 2 and 4 percent respectively [6,7]. Malformations due to twinning itself include conjoined twins, acardiac acephalic twins, holoprosencephaly and sirenomelia. Malformations due to vascular communications on a shared placenta include acardia, microcephaly, hydrancephaly, aplasia cutis, intestinal atresia and limb reduction defects. In monozygotic twinning there may be unequal allocation of the blastomere, discordant anomalies, and unequal placental share.

Monozygotic twinning is differentiated by the timing of embryo division after fertilization. If division occurs within the first 72 hours, two distinct embryos are formed each with two chorions and two amnions, and therefore termed dichorionic, diamniotic. Placentation in this case will result in two placentas with separate circulations that can either be separate masses or fused together into a single mass. If division occurs within 4-8 days of fertilization the chorion has differentiated, and this results in two distinct embryos with one chorion and two amnions. It is therefore monochorionic, diamniotic and there will be a single shared placenta. This is the most common type of monochorionic placentation and has the most common associated complications. At 8-12 days after fertilization, both the chorion and amnion have differentiated and results in two distinct embryos within a single chorion and amnion, therefore monochorionic, monoamniotic which also a single shared placenta. These twin pregnancies are at risk for cord entanglement and fetal demise of one or both twins. After 12 days, conjoined twinning results from the incomplete division of the embryo.

In-vitro fertilization (IVF) results in an increased risk of multiple gestation and the risk increases with the number of embryos transferred. In 1999 the American Society of Reproductive medicine began an effort to reduce the chances of multifetal gestation that resulted in fewer embryos being transferred, a reduction in twin and higher order gestation and resulted in an increase in percentage of live births [8].

### **Imaging and complications of monochorionicity**

On ultrasonography, a monochorionic gestation is diagnosed as a single placental mass, absence of the twin peak sign, membrane less than 2 mm thick, and visualization of the T-sign. The T-sign is where the membrane creates a perpendicular plane with the placenta. The most accurate time to assess this is within the first trimester. Lee and colleagues in 2006 demonstrated a 96% accuracy with first trimester sonography in determining chorionicity compared to pathological examination [9]. In the second trimester, confirmation of like-sex twins helps confirm monochorionic twin gestation. Opposite sex twins are dichorionic with the exception of very rare genetic situations.

Between fetuses in a monochorionic gestation, vascular communications are the underlying reason for multiple complications including twin-twin transfusion syndrome (TTTS), twin reversed arterial perfusion (TRAP) sequence, twin anemia polycythemia sequence (TAPS), and selective fetal intrauterine growth restriction (sIUGR). In monochorionic gestation, the risk of fetal demise is significantly increased compared to dichorionic twin gestation. When there is a twin demise, the resulting hypotension in the dying fetus may result in shunting of blood from the co-twin across these anastomoses. The reported incidence of co-twin demise is 12-25% and neurological injury occurs in 18-25% of survivors [10]. If there is evidence of impending fetal demise selective reduction of the affected twin by either radiofrequency ablation or cord coagulation may be undertaken to prevent injury or death in the co-twin. However, there is currently no consensus on the optimal technique for selective reduction in monochorionic twin gestation [11].

Surveillance for monochorionic twins should include the first trimester ultrasound assessment of chorionicity and assessment of the nuchal translucency. There may be some findings that may indicate an increased risk of developing complications. Findings that suggest impending TTTS include crown-rump discordance, nuchal translucency >95<sup>th</sup> percentile with a 20% discordance between the twins, and reversal or absent ductus venosus a-wave. Starting at approximately 16 weeks, surveillance with ultrasound should be undertaken every two weeks evaluating the maximum vertical pocket (MVP) of fluid in each gestational sac. Although evidence is lacking, some will evaluate the middle cerebral artery (MCA) peak systolic velocity in each fetus in order to rule out TAPS. TAPS may occur without fluid discordance or fetal growth discordance. In addition, fetal growth should be assessed monthly to exclude sIUGR. In the second trimester, there may be abdominal circumference discordance, membrane folding, velamentous cord insertion for the donor and placental echogenicity noted that may again point to the possible development of TTTS. With these findings surveillance frequency may be increased. If at any point there is fluid discordance between the twins with an MVP of <2 cm in one sac and >8 cm in the other, TTTS should be considered in the differential [13].

### **Twin-Twin Transfusion Syndrome (TTTS)**

The most common complication of monochorionic twinning is TTTS (see figure 1) and it occurs in 10-15 percent of monochorionic twins and severe cases occur in nearly a quarter of cases. Selective IUGR occurs concomitantly in 20% of cases. TTTS causes 17% of all perinatal mortality in twins and if left untreated can result in 90% mortality of one or both twins.. Progression may be unpredictable and sudden deterioration may occur resulting in the risk of a co-twin demise. Even with the best treatment perinatal morbidity and mortality remains significant [13].

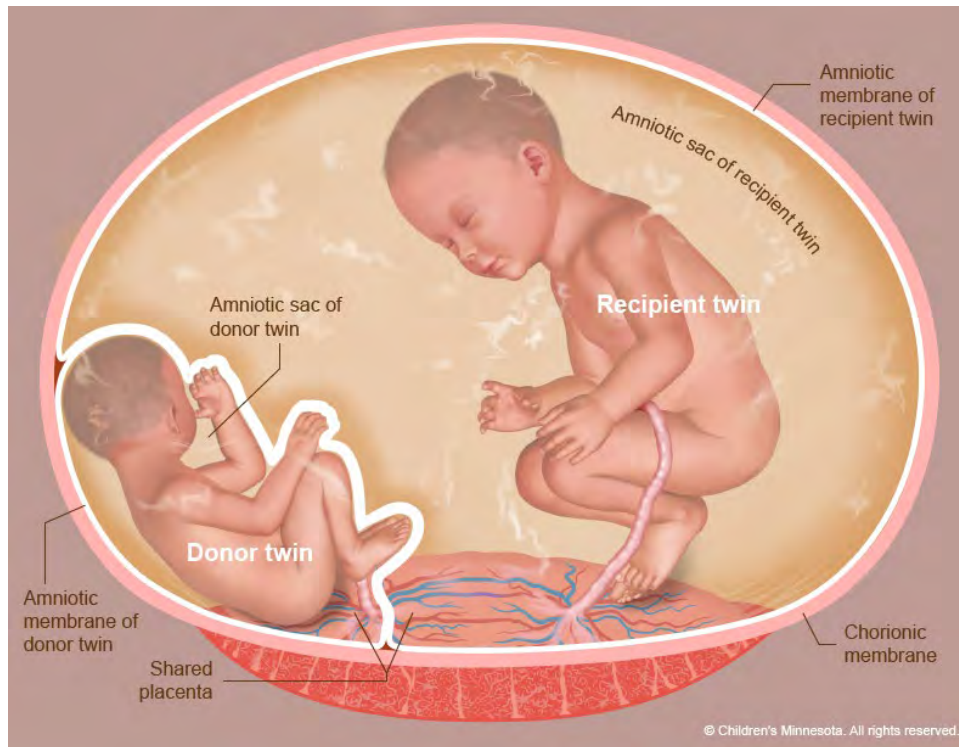


Figure 1: Picture of TTTS. Reproduced with Permission from the Midwest Fetal Care Center and Children's Minnesota.

Vascular anastomoses are near universal in monochorionic twin gestation and they are the prerequisite for TTTS but not the inciting factor. There are three types of anastomoses including bidirectional artery-to-artery and vein-to-vein anastomoses and artery-to-vein anastomoses resulting in unidirectional flow from either fetus. There is variation in the size, number and direction. Although most are visualized on the surface of the placenta there are also deep artery-to-vein communications.

TTTS results from unbalanced flow across vascular anastomoses within the shared placenta. Bidirectional anastomoses may compensate for the unidirectional flow through artery-to-vein communications. Artery-to-artery communications, if identified, are associated with a nine-fold reduction in TTTS and cases with TTTS are more likely to have vein-to-vein connections [14,15]. If this unbalanced flow is significant, it results in a donor twin that is hypodynamic and hypovolemic resulting in decreased renal perfusion, activated renin-angiotensin-aldosterone system, subsequent development of oliguria, oligohydramnios, and decreased placental perfusion that may result in fetal growth restriction. The recipient twin develops hypervolemia, polyuria, polyhydramnios, and hypertensive cardiomyopathy. There is down regulation of renin and increased natriuretic peptides including ANP, BNP and endothelin-1 as well as an increase in troponin levels [16,17]. Diagnosis of TTTS is one of exclusion, as many other diagnoses may mimic the disorder. These include sIUGR, subjective fluid discordance, dichorionic twin gestation with



fluid discordance, twins discordant for either an anomaly or infection and TAPS. Severe TTTS diagnosed early in gestation and untreated results in 80 to 100 percent mortality of at least one twin.

The most widely used staging system for TTTS is the Quintero system [18] A sequence of oligo-polyhydramnios (MVP in donor sac is less than 2cm and MVP in recipient sac is greater than 8cm) is present in all cases with severity increased as below:

Stage I: Bladder is visualized in both fetuses, no fetal distress noted.

Stage II: Bladder is non-visualized in donor (after 60 minutes of observation), the donor is “stuck” with severe oligohydramnios/anhydramnios.

Stage III: Critically abnormal Doppler studies including absent or reversal of umbilical artery end-diastolic flow (A/REDF), reversal of the ductus venosus a-wave, or pulsatile umbilical vein flow.

Stage IV: Presence of ascites or frank hydrops in either the donor or recipient fetus.

Stage V: Death of either twin.

There are additional nonvalidated staging systems that have modified the Quintero system with the addition of multiple cardiac indices such as the Cincinnati modification and CHOP scores, the presence or absence of an artery-to-artery anastomosis, and combining stages I and II as examples [19-21].

The majority of cases are diagnosed in the second trimester and the disease may not progress in a predictable manner. Stage I and II disease may either resolve or stabilize in approximately 60% of cases [22]. Despite this, Stage I disease is still associated with significant morbidity and mortality [23]. Without treatment stage III and above is associated with poor prognosis.

There are several treatments that have been utilized for TTTS. In the past serial amnioreduction was utilized mainly for maternal discomfort from polyhydramnios. The summary of the literature describes an overall survival of approximately 60% when amnioreduction is utilized [24]. However, neurological abnormalities in these patients ranges between 18-26%. In the setting of Stage III disease in which there are Doppler abnormalities, the success of amnioreduction is severely limited. For example, when there is absent end-diastolic flow in the donor there is a 34% chance of survival [24].

Only two randomized trials have been performed comparing amnioreduction to laser ablation (discussed below) of vascular anastomoses. Senat and associates in 2004 reported increased survival to 6 months of age with laser ablation versus serial amnioreduction, 76 percent and 51 percent respectively [49]. Furthermore there was a reduction in neurological morbidity in the laser group versus the amnioreduction group [25]. Also, amnioreduction is not without risk and may cause bleeding and chorioamniotic membrane separation. This can make subsequent fetoscopic procedures more difficult, and for this reason amnioreduction is not recommended or performed by some centers.

The single amnioreduction paradox was described where an amnioreduction was performed and TTTS seemingly resolved with normalization of fluid in both gestational sacs. This was likely due to an inadvertent septostomy within the dividing membrane. Approximately 20% of patients with TTTS will respond in this fashion. Therefore, a randomized trial comparing amnioreduction to deliberate septostomy was undertaken. This study showed no difference in the survival of at least 1 infant (78% vs 80%, respectively). Septostomy, however, resulted in patients requiring more procedures [29]. For this reason, septostomy has become less favorable treatment option for TTTS.

Cord coagulation of one twin utilizing radiofrequency ablation, bipolar cautery, and laser coagulation of the umbilical cord is another option that may be utilized, usually in the setting of impending demise of one twin.

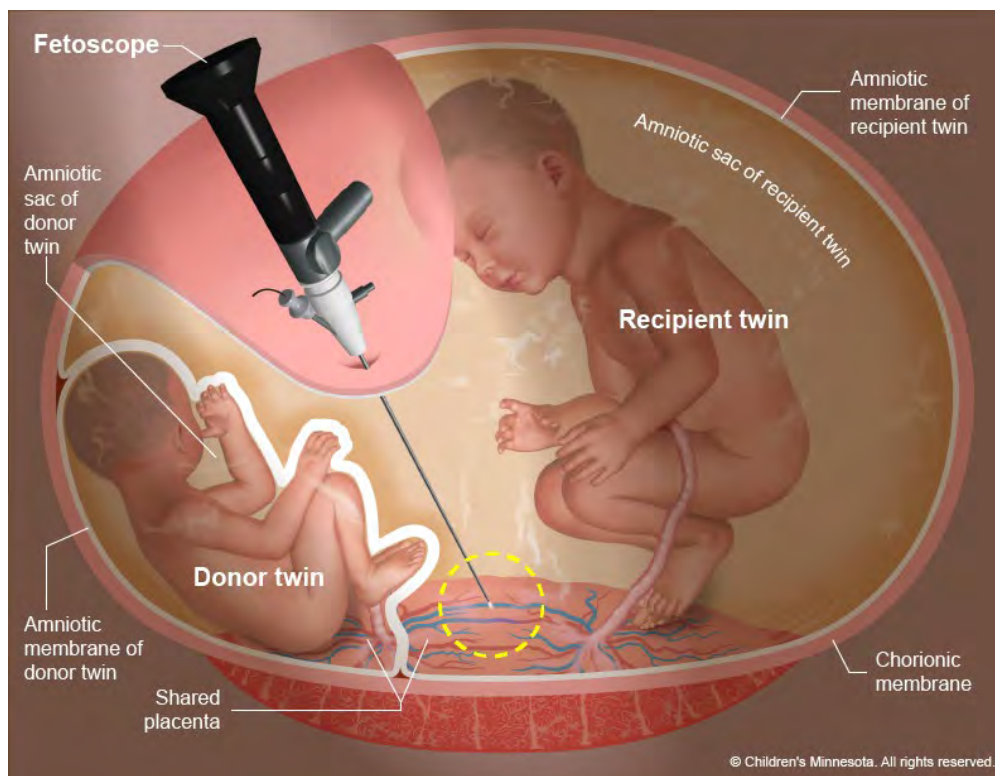


Figure 2: Operative Fetoscopy for TTTS. Reproduced with Permission from the Midwest Fetal Care Center and Children's Minnesota.

There is wide agreement that the preferred therapy for severe TTTS (stages II and greater) is fetoscopic laser ablation of the surface anastomoses (see figure 2). There is currently no consensus on treatment for Stage I disease [22]. Definitive therapy by fetoscopic laser ablation can be undertaken in most cases between 16 weeks and 26 weeks and 6 days.

In most cases fetoscopic laser photocoagulation is a single port technique with either direct entry or Seldinger technique into the recipient sac. The port utilizes 3-operating channels for utilization of the telescope, fluid exchange and laser fiber. The laser used is either diode 980 nm or ND:YAG 1064 nm and the laser diameter is no more than 600 microns in diameter. The procedure may be performed under local or regional anesthesia. In cases of a posterior placenta there is a direct approach to insertion of the fetoscope. The sight of entry is chosen to enter the recipient twin's sac and allowing complete visualization of the intertwin membrane and vascular equator. After local anesthesia is injected a small nick is made with an 11-blade scalpel. The operative sheath is then inserted under ultrasound guidance by either a direct or Seldinger technique. Ultrasound is primarily used to guide the fetoscope toward the placenta surface. Once the placenta is visualized, guidance is mainly through the fetoscopic view. Ultrasound is also utilized to monitor fetal status. The most challenging portion of the procedure is mapping the vascular anastomoses on the placental surface. The fetoscope is methodically moved along the vascular equator and each unpaired anastomosis is documented. The vessels should be followed toward their respective cord insertion to ensure that it is not paired and to identify the type of anastomoses. Once each anastomosis is documented, the laser fiber is inserted and each visible anastomosis is ablated. The vascular equator is again evaluated to ensure all unpaired vessels have been treated. An amnioreduction is performed at the conclusion of the procedure.

Laser ablation, although the preferred treatment, does have some limitations. There may be missed anastomoses, deep vessels may go undetected, and some treated anastomoses may recannulate in up to a third of cases [34,35]. In one study of placental pathology, 8/15 placentas had atypical anastomoses [35]. For this reason, persistent TTTS and TAPS may occur as complications. For this reason, the Solomon technique was introduced. With Solominization, after each anastomosis is ablated a thin line of placental tissue is ablated along the entire length of the vascular equator. In a recent study the rate of recurrent TTTS or TAPS was 21% in the selective group and 4% in the Solomon group. Although these complications were significantly reduced, overall survival was the same in both groups [36].

### **Complications of Selective Fetoscopic Laser Photocoagulation**

Even in experienced hands complications from fetoscopic laser ablation remain significant. One series reported complications in 31% of cases within 7 days of the procedure and in 39% of those greater than 7 days after the procedure. The most common complications include premature rupture of membranes, premature delivery and complications involving the membranes such as chorioamniotic membrane separation [37].

Contemporary survival statistics are best reflected in the recent Solomon trial. Overall survival in the standard and Solomon group were 73% and 74%, at least one twin survivor in 87% and 85%, and double survival in 60% and 64% respectively [36]. As far as long term neurological sequelae, follow-up of the Eurofetus Trial demonstrated no difference in the evaluations between the laser and amnioreduction groups, however when broken down by stage, laser treated survivors with severe TTTS had significantly improved long term neurological outcomes [37].

Surveillance following laser ablation includes weekly ultrasound surveillance with assessment of fluid pockets and Doppler studies of both fetuses to evaluate for persistent or recurrent TTTS as well as TAPS. Cervical length surveillance is controversial as is the use of cerclage, which has limited evidence of efficacy in the setting of TTTS.

### **Twin Reversed Arterial Perfusion (TRAP) Sequence**

Twin reversed-arterial-perfusion sequence or TRAP sequence occurs with a frequency of 1 in 35,000 births. It is a rare disorder with lethal consequences. In this condition, there is a normally formed pump or donor twin as well as an abnormally formed recipient twin, which is called an acardiac twin. There is either no heart or a rudimentary heart. The etiology relies on a large artery-to-artery shunt with corresponding vein-to-vein shunt. The perfusion pressure of the pump twin is greater than that of the acardiac twin who receives deoxygenated arterial blood through its umbilical arteries [38]. The lower body of the acardiac twin is perfused resulting in abnormal development of the upper body. If the head does not develop this is called an acephalic acardiac twin. The pump twin is not only providing perfusion to itself, it is also supporting the acardiac twin. This results in a high cardiac output state and may lead to heart failure and demise.

The natural history of the disease results in death in 50-75 percent of cases [39]. Intervention for this condition to prevent or reverse hydrops in the pump twin can be accomplished utilizing radiofrequency ablation (RFA), bipolar coagulation or interstitial laser. RFA has become the preferred technique resulting in cessation of blood flow to the acardiac twin. Criteria for therapy varies between centers; however, the acardiac twin must be large, measuring at least 50 percent of the size of the pump twin. Others combine size with evidence of impending hydrops such as Doppler and cardiac changes. The procedure can be done under local or regional anesthesia and an RFA needle is introduced into the cord insertion site within the acardiac twin. RFA devices vary, but the ideal device has a small caliber, 17 gauge, and creates a finite area of thermal coagulation.

Cessation of flow is confirmed by color flow Doppler. Lee and colleagues reported the largest series of 98 cases treated within The North American Fetal Therapy Network with 80% survival delivering at an average of 36 weeks' gestation [40].

### **Level of Evidence**

Grade B, Level 2-3 (cohort and case-control studies)

**References**

1. Martin JA, Hamilton BE, Osterman MJ. Three decades of twin Births in the United States, 1980-2009. NCHS Data Brief. 2012 Jan;(80):1-8
2. Mathews TJ, MacDorman FM: Infant mortality statistics from the 2003 period linked birth/infant death data set. Natl Vital Stat Rep 54:1, 2006
3. Walker MC, Murphy KE, Pan S, et al: Adverse maternal outcomes in multifetal pregnancies. BJOG 111:1294, 2004
4. Carroll SGM, Tyfield L, Reeve L, et al: Is zygosity or chorionicity the main determinant of fetal outcome in twin pregnancies? Am J Obstet Gynecol 193:757, 2005
5. Wenstrom KD, Syrop CH, Hammitt DG, van Voorhis BJ. Increased risk of monochorionic twinning associated with assisted reproduction. Fertil Steril 1993;60:510-4.
6. Cameron AH, Edwards JH, Derom R, et al: The value of twin surveys in the study of malformation. Eur J Obstet Gynecol Reprod Biol 14:347, 1983.
7. Kohl SG, Casey G: Twin gestation. Mt Sinai J Med 42:523, 1975.
8. Jain T, Missmer SA, Hornstein MD: Trends in embryo-transfer practice and in outcomes of the use of assisted reproductive technology in the United States. N Engl J Med 350:1639, 2004.
9. Lee YM, Cleary-Goldman J, Thaker HM, et al: Antenatal sonographic prediction of twin chorionicity. Am J Obstet Gynecol 195:863, 2006.
10. Ong SS, Zamora J, Khan KS, et al: Prognosis for the co-twin following single-twin death: a systematic review. BJOG 113: 992-998, 2006
11. Roman A, Papanna R, Johnson A, et al: Selective reduction in complicated monochorionic pregnancy: radiofrequency ablation vs. bipolar cord coagulation. Ultrasound Obstet Gynecol 36: 37-41, 2010
12. Society for Maternal-Fetal Medicine, Simpsom LL. Twin-twin transfusion syndrome. Am J Obstet Gynecol 208: 3-18, 2013.
13. Lewi L, Jani J, Blickstein I, et al. The outcome of monochorionic diamniotic twin gestations in the era of invasive fetal therapy: a prospective cohort study. Am J Obstet Gynecol 199: 514e1-8, 2008.
14. Tan TY, Taylor MJ, Wee LY, Vanderheyden T, Wimalasundera R, Fisk NM. Doppler for artery-artery anastomosis and stage-independent survival in twin-twin transfusion. Obstet Gynecol 2004;103:1174-80.
15. Diehl W, Hecher K, Zikulnig L, Vetter M, Hackeloer BJ. Placental vascular anastomoses visualized during fetoscopic laser surgery in severe mid-trimester twin-twin transfusion syndrome. Placenta 2001; 22:876-81
16. Von Mieghem T, Done E, Gucciardo L, et al. Amniotic fluid markers of fetal cardiac dysfunction in twin-to-twin transfusion syndrome. Am J Obstet Gynecol 2010;202 48 e1-7
17. Bajoria R, Sullivan M, Fisk NM. Endothelin concentrations in monochorionic twins with severe twin-twin transfusion syndrome. Hum Re- prod 1999;14:1614-8.
18. Quintero RA, Morales WJ, Allen MH, et al: Staging of twin-twin transfusion syndrome. J Perinatol 19:550, 1999

19. Michelfelder E, Gottliebson W, Border W, et al: Early manifestations and spectrum of recipient twin cardiomyopathy in twin-twin transfusion syndrome: Relation to Quintero stage. *Ultrasound Obstet Gynecol* 30:965, 2007
20. Rychik J, Tian Z, Bebbington M, et al: The twin-twin transfusion syndrome: Spectrum of cardiovascular abnormality and development of a cardiovascular score to assess severity of disease. *Am J Obstet Gynecol* 197:392, 2007
21. Shah AD, Border WL, Crombleholme TM, et al: Initial fetal cardiovascular profile score predicts recipient twin outcome in twin-twin transfusions syndrome. *J Am Soc Echocardiogr* 21(10):1105, 2008
22. Stamillo DM, Fraser WD, Moore TR: Twin-twin transfusion syndrome: an ethics based and evidence-based argument for clinical research. *Am J Obstet Gynecol* 203: 3-16, 2010
23. Emery SP, Hasley SK, Catov JM, et al. North American Fetal Therapy Network: intervention versus expectant management for stagel twin-twin transfusion syndrome. *Am J Obstet Gynecol* 215: 346.e1-7, 2016.
24. G. Mari, A. Roberts, L. Detti, E. Kovanci, T. Stetos, R.O. Bahado-Singh, et al. Perinatal morbidity and mortality rates in severe twin-twin transfusion syndrome: results of the International Amnioreduction Registry *Am J Obstet Gynecol*, 185 (2001), pp. 708-715
25. Senat M-V, Deprest J, Boulvain M, et al: Endoscopic laser surgery versus amnioreduction for severe twin-to-twin transfusion syndrome. *N Engl J Med* 351: 136, 2004
26. Crombleholme TM, Shera D, Lee H, Johnson M et al. A prospective randomized, multicenter trial of amnioreduction vs selective fetoscopic laser photocoagulation for the treatment of severe tin-twin transfusion syndrome. *Am J Obstet Gynecol*. 2007 Oct;197(4):396.e1-9.
27. Adzick SN, Thom EA, Spong CY, et al: A randomized trial of prenatal versus postnatal repair of myelomeningocele. *N Engl J Med* 364: 993-1004, 2011
28. G.R. Saade, M.A. Belfort, D.L. Berry, T.H. Bui, L.D. Montgomery, A. Johnson, et al. Amniotic septostomy for the treatment of twin oligohydramnios-polyhydramnios sequence. *Fetal Diagn Ther*, 13 (1998), pp. 86-93
29. Moise KJ, Dorman K, Lamvu G, et al. A randomized trial of amnioreduction versus septostomy in the treatment of twin-twin transfusion syndrome. *Am J Obstet Gynecol* 193: 701-7, 2005.
30. DeLia JE, Rogers JG, Dixon JA. Treatment of placental vasulature with a neodmium-yttrium-aluminum-garnet laser via fetoscopy. *Am J Obstet Gynecol*. 1985 Apr 15;151(8):1126-7.
31. Quintero RA, Comas C, Bornick PW, et al. Selective versus non-selective laser photocoagulation of placental vessels in twin-to-twin transfusion syndrome. *Ultrasound Obstet Gynecol*. 2000 Sep;16(3):230-6.
32. Quintero RA, Ishii K, Chmait RH, et al. Sequential selective laser photocoagulation of communicating vessels in twin-twin transfusion syndrome. *Matern Fetal Neonatal Med*. 2007 Oct;20(10):763-8.
33. Lewi L, Jani J., Cannie M., et al: Intertwin anastomoses in monochorionic placentas after fetoscopic laser coagulation for twin-to-twin transfusion syndrome: is there more than meets the eye? *Am J Obstet Gynecol* 2006; 194: pp. 790-795

34. Lopriore E., Middeldorp J.M., Oepkes D., Klumper F.J., Walther F.J., and Vandenbussche F.P.: Residual anastomoses after fetoscopic laser surgery in twin-to-twin transfusion syndrome: frequency, associated risks and outcome. *Placenta* 2007; 28: pp. 204-208
35. Wee LY, Taylor M, Watkins N, et al. Characterization of deep arterio-venous anastomoses within monochorionic placentae by vascular casting. *Placenta* 26: 19-24, 2005.
36. Slaghekke F, Lopriore E, Lewi L, et al. Fetoscopic laser coagulation of the vascular eqyator versus selective coagulation for twin-to-twin transfusion syndrome: an open-label randomized controlled trial. *Lancet* 2014; 383: 2144–51.
37. Salomon LJ, Ortqvist L, Aegerter P, Bussieres L, Staracci S, Stirnemann JJ, Essaoui M, Bernard JP, Ville Y. Long-term developmental follow-up of infants who participated in a randomized clinical trial of amniocentesis vs laser photocoagulation for the treatment of twin-to-twin transfusion syndrome. *Am J Obstet Gynecol* 203: 444.e1-7, 2010.
38. Jones KL: *Smith's Recognizable Patterns of Human Malformation*, 5th ed. Philadelphia, Saunders, 1997, p 658.
39. Moore TR, Gale S, Benirschke K: Perinatal outcome of forty nine pregnancies complicated by acardiac twinning. *Am Obstet Gynecol* 163:907, 1990.
40. Lee H, Bebbington M, Crombleholme T. The North American Fetal Therapy Network Registry data on outcomes of radiofrequency ablation for twin-reversed arterial perfusion sequence. *Fetal Diagn Ther* 33: 224-9, 2013.

## Fetal Airway

David T. Schindel

### Introduction

There are a number of anomalies that may lead to difficulty in establishing a neonatal airway. At delivery, a multi-disciplinary effort must be made to minimize the loss of airway and resultant postnatal hypoxia that may have permanent devastating effects. Described here are the most common lesions identified prenatally.

### Fetal Oropharyngeal Lesions

Oropharyngeal lesions of the fetus are rare but are known to be the cause of immediate respiratory distress at delivery. These lesions include congenital ranula, epulis, epignathus and foregut duplication cysts. Ranulas are the result of a disruption of minor salivary ducts leading to extravasation of mucus into nearby tissue resulting in a mucus cyst[1]. These lesions may arise from the floor of the mouth and may push the tongue upward obstructing the airway[2]. A congenital epulis is a solid granular cell tumor arising from the alveolar ridge. These lesions are solid, benign and may present as large pedunculated lesions extending from the maxilla[3]. An epignathus is an oropharyngeal teratoma arising from the palate[3]. These lesions often have solid and cystic components and contain calcifications. Often these lesions extend into both the oral cavity and intracranial structures and can be associated with maternal serum alpha fetoprotein elevation[3]. These lesions are more commonly diagnosed on fetal US after 20 weeks gestation and are more fully characterized by fetal MRI. If associated with polyhydramnios, these lesions may be best managed by an EXIT (ex-partum intrauterine therapy) procedure described in the section below[3]. A ranula cyst may be simply incised or excised when thereby clearing the airway for delivery. Similarly, epulis is well managed by EXIT allowing a curative excision of the mass which facilitates assessment of the airway by laryngoscopy[3]. A fetal airway obstructing epignathus may be more problematic as the resection is more complex and unable to be completed during a typical EXIT procedure. Those lesions associated with polyhydramnios are likely to require EXIT with control of the airway by tracheostomy. After an airway is established, further assessment and excision of the mass following delivery is performed[3]. Foregut duplication cysts of the hypopharynx are extremely rare. These lesions can be solid or cystic and often contain heterotopic gastric epithelium. Due to mass effect, these lesions may cause airway obstruction[4]. On fetal US and MRI, the presence of tracheal dilatation has been associated with the need for EXIT in cases of oral cavity tumors[5].



### **Fetal Neck Masses**

Cervical neoplasms may pose a significant risk to the fetus with a nearly 20% risk of intra-uterine fetal demise (IUFD) and a 35% risk of death prior to airway stabilization immediately after delivery[6, 7]. Obstruction of the trachea and esophagus can result in polyhydramnios and preterm labor, and local compression can lead to craniofacial defects and cranial nerve injury. Highly vascular lesions can lead to cardiac failure with non-immune fetal hydrops and subsequent IUFD[8]. The majority of these lesions will be comprised of either cervical teratoma, lymphatic malformations (historically referred to as cystic hygromas) or other vascular malformations[9]. Rarely neck masses can include thymic cysts, intestinal duplication cysts or congenital neuroblastoma[10, 11]. These lesions are readily identified on prenatal ultrasound. Once the presence of a cervical mass has been recognized, fetal MRI should be obtained to better characterize the mass, specifically to distinguish between lymphatic malformations and teratoma. This distinction is based on the presence or absence of fat within the lesion[12]. The tracheoesophageal displacement index (TEDI) can be a useful prognostic measurement. The TEDI is defined as the sum of the lateral and ventral displacement of the trachea and esophagus from the ventral-most aspect of the cervical spine[13]. In a series of 24 prenatally diagnosed neck masses all patients with a TEDI of >12mm had a complicated airway whereas only 46% of those with a TEDI <12mm had a complicated airway. Furthermore, the authors found that the presence of a cervical teratoma with polyhydramnios also increased the risk for a complicated airway[13]. Many teratomas are noted to rapidly enlarge during the last trimester and therefore close surveillance is necessary to identify fetuses at risk for airway issues. Large masses that cause significant extension of the neck require delivery via cesarean section due to the risk of dystocia[14]. In the presence of fetal hydrops prior to 30 weeks gestation, open fetal resection may be considered although this is uncommon. After delivery, immediately securing the airway is paramount. This cannot be accomplished quickly enough in up to 35% of cases. If the airway cannot be secured, the neonate dies immediately due to airway compromise[6, 7]. Left untreated, large neck masses can carry an 80-100% mortality rate[14]. For this reason, an EXIT procedure is advocated to permit adequate time for airway stabilization prior to complete delivery[15]. Post-delivery and post-resection hypothyroidism and hypoparathyroidism are the most common complications, particularly with cervical teratomas[14]. Therefore, an endocrinology work-up should be initiated with consultation as indicated. Given the small malignant potential for cervical teratomas, screening for recurrence should also be implemented by following alpha-fetoprotein levels and obtaining surveillance imaging. Fetal cervical lymphatic malformations may cause airway compromise at delivery but less frequently. Lesions at risk for airway compromise are typically associated with polyhydramnios[16]. On fetal MRI, these lesions may be seen to extend to the aryepiglottic folds and larynx and involve the tongue, thereby causing obstruction of the airway. Such lesions have been associated with the need for EXIT to tracheostomy to assure proper airway patency and may be associated with a long-term dependency on tracheostomy to insure an adequate airway[15, 16]. The ability to predict airway involvement by a lymphatic malformation is vital in assuring proper airway management at the time of delivery. Lymphatic malformations have been shown to have variable prenatal growth patterns and typically

continue to grow until the end of gestation underscoring the need for persist surveillance up to delivery[17].

### **Congenital High Airway Obstruction Syndrome (CHAOS)**

Congenital high airway obstruction syndrome is a very rare entity with a very poor prognosis. CHAOS is characterized by an intrinsically obstructed upper airway, the most common entity being laryngeal atresia[18]. Additional causes include laryngeal and tracheal webs, laryngeal cysts, tracheal atresia, subglottic stenosis or atresia and tracheal or laryngeal agenesis have also been described[18]. The obstruction of the airway leads to dilatation of the airway below the obstruction, flattening of the diaphragm and massive enlargement of the lungs from entrapped fluid[9]. Because of elevated intrathoracic pressures, venous return can be compromised leading to ascites, placentomegaly and fetal hydrops with heart failure[19]. Oligohydramnios is a common finding associated with CHAOS due to the obstruction of normal amniotic fluid formation[19]. This finding should prompt the evaluation for associated Fraser syndrome (renal or ureteral agenesis, cryptophthalmos, syndactyly, ambiguous genitalia and laryngeal atresia). CHAOS may also be a part of Cri-du-Chat syndrome, short rib polydactyly syndrome and velocardiofacial syndrome[20]. Studies have demonstrated the importance of MRI in defining the level of obstruction and excluding extrinsic causes of obstruction as early as 16<sup>th</sup> week gestation[9]. Prenatal diagnosis of CHAOS is necessary to achieve perinatal survival when possible. The EXIT procedure has been successfully employed to achieve an airway for delivery, often by tracheostomy, in cases of laryngeal atresia having an adequate patent cervical trachea[12, 18, 19]. Fetoscopic approaches have also been described. In these cases, the findings of fetal vocal cords suggesting a tracheal web have allowed successful fetoscopic perforation of the web and airway deobstruction[21]. In most instances, management of the airway, particularly in regards to long-term reconstruction in children with CHAOS, remains challenging.

### **Micrognathia**

Fetuses having mandibular anomalies are at risk for respiratory distress syndrome upon delivery. This emergency is typically the result of the significant mandibular hypoplasia allowing the tongue to obstruct the upper airway[22]. Micrognathia is the most common of these anomalies and is commonly associated with many different fetal syndromes such as cardiac and skeletal dysplasias, Treacher Collins and Goldenhar[23]. Severe cases are commonly associated with polyhydramnios likely due to the obstruction by the tongue creating difficulties for swallowing. In severe cases, the jaw index (mandibular anterior-posterior diameter normalized to biparietal diameter) is typically less than the 5<sup>th</sup> percentile[24]. This finding has been employed to select fetuses at risk for respiratory compromise prompting delivery by the EXIT procedure. An appropriate airway is often achieved by endotracheal intubation facilitated by a

flexible bronchoscope. In severe cases, a tracheostomy might be required to achieve an appropriate airway allowing separation from the placental circulation[22].

### **EXIT (Ex-Utero Intrapartum Therapy) Procedure**

Contrary to a routine cesarean section, deep maternal anesthesia is required during an EXIT procedure to maintain complete uterine relaxation and preserve utero-placental circulation so the fetus does not undergo premature transition from fetal to neonatal circulation. In a cesarean section, contraction of the uterus is ideal because it is hemostatic; in an EXIT procedure uterine contraction would be detrimental to the fetus but also puts the mother at greater risk for hemorrhage. During an EXIT-to-airway procedure, the uterus is exposed and a hysterotomy is made to deliver the fetus' head and neck. Direct laryngoscopy is performed to assist with endotracheal intubation. Means to establish an airway can be escalated using bronchoscopy or tracheostomy if laryngoscopy is not successful. The trachea is oftentimes deviated, and this displacement must be recognized prior to tracheostomy. In cases of large cystic lesions, decompression of the cyst may facilitate establishing an airway by relieving any airway compression. In order to obtain an appropriate airway, resection of the mass may be necessary. This is done while remaining on utero-placental circulation. This procedure is termed "EXIT-to-resection." In some rare instances, EXIT-to-ECMO may be required to facilitate separation of the fetus from the utero-placental circulation while maintaining appropriate perfusion. In these instances, EXIT-to-ECMO can allow subsequent opportunities for imaging and anatomical clarification of an anomaly thereby facilitating reconstruction of a complex malformation. Once an airway has been established, the umbilical cord can be divided and the baby completely delivered. The EXIT procedure has been shown to be a safe modality associated with minimal maternal morbidity and normal future conception rates[25].

### **Level of Evidence**

Grade B, Level 3a/3b (case-control studies)

## References

- [1] Harrison JD. Modern management and pathophysiology of ranula: literature review. *Head & neck* 2010;32(10):1310-20.
- [2] Gul A, Gungorduk K, Yildirim G, Gedikbasi A, Ceylan Y. Prenatal diagnosis and management of a ranula. *The journal of obstetrics and gynaecology research* 2008;34(2):262-5.
- [3] Laje P, Howell LJ, Johnson MP, Hedrick HL, Flake AW, Adzick NS. Perinatal management of congenital oropharyngeal tumors: the ex utero intrapartum treatment (EXIT) approach. *Journal of pediatric surgery* 2013;48(10):2005-10.
- [4] Knowles KJ, Berkovic J, Gungor A, Al Shaarani M, Lockhart V, Al-Delphi F, et al. Oral foregut duplication cysts: A rare and fascinating congenital lesion. Case report and review of the literature. *American journal of otolaryngology* 2017;38(6):724-5.
- [5] Ventura W, Novoa RH, Lazarte-Rantes CI, Castillo-Urquiaga W, Zarate-Girao M, Hernandez-Mansilla C, et al. Tracheal dilatation as sign of fetal airway obstruction in case of oral cavity tumor. *Ultrasound in obstetrics & gynecology : the official journal of the International Society of Ultrasound in Obstetrics and Gynecology* 2017.
- [6] Berge SJ, von Lindern JJ, Appel T, Braumann B, Niederhagen B. Diagnosis and management of cervical teratomas. *The British journal of oral & maxillofacial surgery* 2004;42(1):41-5.
- [7] PJ B. Congenital Tumors. In: Kelling JW e, editor *Fetal and Neonatal Pathology*. London: Springer-Verlag; 1997, p. 273-94.
- [8] Hirose S, Sydorak RM, Tsao K, Cauldwell CB, Newman KD, Mychaliska GB, et al. Spectrum of intrapartum management strategies for giant fetal cervical teratoma. *Journal of pediatric surgery* 2003;38(3):446-50; discussion -50.
- [9] Guimaraes CV, Linam LE, Kline-Fath BM, Donnelly LF, Calvo-Garcia MA, Rubio EI, et al. Prenatal MRI findings of fetuses with congenital high airway obstruction sequence. *Korean journal of radiology* 2009;10(2):129-34.
- [10] Billings KR, Rollins NK, Timmons C, Biavati MJ. Infected neonatal cervical thymic cyst. *Otolaryngology--head and neck surgery : official journal of American Academy of Otolaryngology-Head and Neck Surgery* 2000;123(5):651-4.
- [11] Hubbard AM, Crombleholme TM, Adzick NS. Prenatal MRI evaluation of giant neck masses in preparation for the fetal exit procedure. *American journal of perinatology* 1998;15(4):253-7.
- [12] Kornacki J, Szydłowski J, Skrzypczak J, Szczepanska M, Rajewski M, Koziolok A, et al. Use of ex utero intrapartum treatment procedure in fetal neck and high airway anomalies - report of four clinical cases. *The journal of maternal-fetal & neonatal medicine : the official journal of the European Association of Perinatal Medicine, the Federation of Asia and Oceania Perinatal Societies, the International Society of Perinatal Obstet* 2017:1-5.
- [13] Lazar DA, Cassidy CI, Olutoye OO, Moise KJ, Jr., Johnson A, Lee TC, et al. Tracheoesophageal displacement index and predictors of airway obstruction for fetuses with neck masses. *Journal of pediatric surgery* 2012;47(1):46-50.
- [14] Cervical Teratoma. In: Bianchi DW CT, D'Alton ME, Malone FD, eds., editor *Fetology: Diagnosis and Management of the Fetal Patient*. New York, NY: McGraw-Hill; 2010, p. 751-8.
- [15] Laje P, Peranteau WH, Hedrick HL, Flake AW, Johnson MP, Moldenhauer JS, et al. Ex utero intrapartum treatment (EXIT) in the management of cervical lymphatic malformation. *Journal of pediatric surgery* 2015;50(2):311-4.
- [16] Schindel DT, Twickler D, Frost N, Walsh D, Santiago-Munoz P, Johnson R. Prognostic significance of an antenatal magnetic resonance imaging staging system on airway outcomes of fetal craniofacial venolymphatic malformations. *The Journal of surgical research* 2017;217:187-90.

- [17] Peranteau WH, Iyooob SD, Boelig MM, Khalek N, Moldenhauer JS, Johnson MP, et al. Prenatal growth characteristics of lymphatic malformations. *Journal of pediatric surgery* 2017;52(1):65-8.
- [18] Shimabukuro F, Sakumoto K, Masamoto H, Asato Y, Yoshida T, Shinhama A, et al. A case of congenital high airway obstruction syndrome managed by ex utero intrapartum treatment: case report and review of the literature. *American journal of perinatology* 2007;24(3):197-201.
- [19] Roybal JL, Liechty KW, Hedrick HL, Bebbington MW, Johnson MP, Coleman BG, et al. Predicting the severity of congenital high airway obstruction syndrome. *Journal of pediatric surgery* 2010;45(8):1633-9.
- [20] Lim FY, Crombleholme TM, Hedrick HL, Flake AW, Johnson MP, Howell LJ, et al. Congenital high airway obstruction syndrome: natural history and management. *Journal of pediatric surgery* 2003;38(6):940-5.
- [21] Martinez JM, Castanon M, Gomez O, Prat J, Eixarch E, Bannasar M, et al. Evaluation of fetal vocal cords to select candidates for successful fetoscopic treatment of congenital high airway obstruction syndrome: preliminary case series. *Fetal diagnosis and therapy* 2013;34(2):77-84.
- [22] Morris LM, Lim FY, Elluru RG, Hopkin RJ, Jaekle RK, Polzin WJ, et al. Severe micrognathia: indications for EXIT-to-Airway. *Fetal diagnosis and therapy* 2009;26(3):162-6.
- [23] Nicolaides KH, Salvesen DR, Snijders RJ, Gosden CM. Fetal facial defects: associated malformations and chromosomal abnormalities. *Fetal diagnosis and therapy* 1993;8(1):1-9.
- [24] Nemeč U, Nemeč SF, Brugger PC, Weber M, Bartsch B, Bettelheim D, et al. Normal mandibular growth and diagnosis of micrognathia at prenatal MRI. *Prenatal diagnosis* 2015;35(2):108-16.
- [25] Zamora IJ, Ethun CG, Evans LM, Olutoye OO, Ivey RT, Haeri S, et al. Maternal morbidity and reproductive outcomes related to fetal surgery. *Journal of pediatric surgery* 2013;48(5):951-5.

## **Anomalies of the Genitourinary Tract**

**Elizabeth O'Hare and Eric Jelin**

### **Introduction**

Anomalies of the genitourinary (GU) system vary greatly in presentation and severity. The genitourinary (GU) system includes the kidneys, ureters, bladder, urethra and genitals which function together to remove toxins and waste from the blood and secrete them from the body in the form of urine. Malformations in any part of the GU tract can disrupt this removal/excretion process and cause fetal disease. Severity of malformations ranges from mild vesicoureteral reflux that resolves in utero on its own to severe congenital anomalies of the kidneys and urinary tract (CAKUT) such as congenital bilateral renal agenesis which is generally fatal. There are many congenital GU anomalies found in children, constituting about 17% of all congenital anomalies [1], but the most common that will be discussed here are vesicoureteral reflux (VUR), hydronephrosis, renal agenesis, prune belly syndrome, multicystic dysplastic kidney (MCDK), and polycystic kidney disease (PKD). For information on bladder exstrophy, please refer to chapter 7 (Abdominal Wall Defects).

### **Main role of the GU tract in fetal development**

The fetal kidneys begin to produce urine at 12 weeks gestational age (GA), which is the main constituent of amniotic fluid by 16 weeks GA. Amniotic fluid immunologically and physically protects the fetus and supplies nutrients (specifically proline) necessary for development [2]. If there is insufficient urine production and/or output, comorbidities secondary to low amniotic fluid volume (oligohydramnios) will most likely develop. Comorbidities include Potter sequence in severe cases, along with milder deformities of the face, heart, and limbs. Other morbidities may result from increased risk of infection or inability to secrete toxins, such as urinary tract infections.

### **Pathophysiology of GU Anomalies**

#### *Genital anomalies*

The male and female reproductive organs make up the genital system. Most anomalies of the genital system, including ambiguous genitalia and hypospadias, are not life-threatening and are not cause for fetal intervention, but do have sexual and societal implications which call for sensitive counseling of the family members.

### *Vesicoureteral reflux*

Primary vesicoureteral reflux (VUR) occurs when the vesicoureteral valve is too short to close the ureter-bladder junction, allowing urine to flow back up into the kidneys. Secondary VUR results when an obstruction along the urinary tract causes urine to flow back up into the kidneys because it cannot flow in the normal direction. This puts the fetus at risk for hydronephrosis and pyelonephritis after delivery.

### *Hydronephrosis*

When urine excretion is blocked in some part of the urinary tract and urine builds up in the ureter and renal pelvis of one or both kidneys, it causes ureteral and renal swelling (hydronephrosis). Most antenatal cases resolve before birth if obstruction is relieved (*transient hydronephrosis*), but severe cases lasting into the third trimester can be representative of an underlying congenital anomaly of the kidney and urinary tract (CAKUT) which may require fetal or neonatal treatment [3]. Severe cases are commonly a result of congenital ureteropelvic junction obstruction, VUR, or lower urinary tract obstruction (LUTO). Common forms of LUTO include *posterior urethral valves (PUV)*, in males, and *urethral atresia* in both males and females. Hydronephrosis caused by LUTO is accompanied by bladder hypertrophy and is associated with high rates of morbidity and mortality because complete obstruction leads to oligohydramnios and progressive renal failure [3]. There are a few different systems implemented to grade hydronephrosis, but that most commonly used system measures the renal pelvic diameter (RPD) in the second or third trimester to estimate the risk of associated CAKUT (RPD: mild: 4 to <10 mm; moderate: >10-15 mm; severe: >15 mm) [3]. The decision for postnatal surgical intervention is most commonly based on resulting CAKUT. Although intervention is most necessary in moderate and severe cases (RPD >10), some mild cases also require intervention [4].

### *Renal Agenesis*

Renal agenesis is characterized by the absence of one (unilateral renal agenesis; URA) or both (congenital bilateral renal agenesis; CoBRA) kidney(s). URA is usually not a cause for concern [5, 6], since urine production and function of the existing kidney tends to compensate for the missing kidney. Conversely, CoBRA is thought to be universally fatal because of anhydramnios and resulting pulmonary hypoplasia. A clinical trial is underway to determine the efficacy of serial amnioinfusions to rescue lung growth (The renal agenesis fetal therapy (RAFT) trial; <https://clinicaltrials.gov/ct2/show/NCT03101891>), but there is currently no approved treatment for CoBRA.

### *Prune Belly/Eagle-Barrett syndrome*

In prune belly syndrome, the abdominal muscles fail to develop, causing compression on the neck of the bladder and secondary obstruction of the ureter(s), which leads to either hydronephrosis, distended bladder, vesicoureteral reflux, and increased risk of infection from urinary stasis. The testes also fail to descend into the scrotum (*bilateral cryptorchidism*). Severity

ranges from slight urinary problems to fatal complete urinary tract obstruction with no renal function.

### *Multicystic Dysplastic Kidney*

Multicystic dysplastic kidney (MCDK) is characterized by cartilage cyst formation in either one or both kidneys and is accompanied by ureteral atresia, leading to a nonfunctioning kidney(s). Unilateral MCDK is almost always consistent with contralateral symptoms which worsen the prognosis, but the fetus has a greater chance for survival in the postnatal period if amniotic fluid volume is high enough for sufficient lung growth. Bilateral MCKD, like CoBRA, is thought to be universally fatal, with very few exceptions in which there is slight function in one of the kidneys that allows for enough urine output for lung development [7]. The origin of MCDK is unknown.

### *Polycystic Kidney Disease (PKD)*

Autosomal recessive polycystic kidney disease (ARPKD) is a genetic disorder arising in infants and fetuses as a result of the autosomal recessive PKHD1 gene on both copies of chromosome 6 [8]. This gene codes for the fibrocystin protein, which is thought to play a role in calcium absorption of primary cilia. A mutation of this gene is thought to upregulate cell proliferation and water uptake, leading to cyst formation. Growing cysts compress surrounding tissues and often cause renal insufficiency or renal failure consistent with oligohydramnios (Potter sequence), hepatic abnormalities (hepatic fibrosis and portal hypertension), and pancreatic problems [9].

## **Fetal Diagnosis**

Most GU malformations are diagnosed during routine ultrasounds in the second trimester (18-22 weeks GA) [10]. Prognosis is better assessed longitudinally as urine production and kidney function can be assessed over multiple exams [3]. Since oligohydramnios is common secondary to GU anomalies, amnioinfusions may be necessary to perform accurate ultrasound diagnosis.

## **Prognosis**

Most GU anomalies are not a major cause for concern. Many resolve in-utero without treatment or can be resolved after birth. There are exceptions, such as MCKD, LUTO, PCKD and CoBRA which can be fatal. In these severe cases, obstruction inhibits urine output and causes oligohydramnios with secondary pulmonary hypoplasia and other deformities (Potter sequence) which ultimately lead to demise either in utero, or after birth due to pulmonary/renal insufficiency. Although not as severe, obstruction in any portion of the GU tract affects normal urine output and can cause urinary stasis, reflux, mild hydronephrosis, and oligohydramnios, putting the fetus at risk for pulmonary hypoplasia, bladder hypertrophy, and infections.



## **Fetal Therapy**

Fetal therapy for GU anomalies is reserved for severe defects. It is directed at preventing renal failure by relieving obstructions and mitigating pulmonary hypoplasia by reestablishing normal amniotic fluid volume. In determining the course of treatment, it is always important to compare possible outcomes. In severe cases of GU anomalies causing oligohydramnios and pulmonary hypoplasia, fetal therapy gives the fetus a chance of survival it would otherwise not have, but in less severe cases, therapy may expose the fetus to unnecessary risk and lead to pregnancy loss. It is essential to properly educate the family on the possible outcomes of fetal therapy versus conservative management before going forward with treatment.

### *Vesico-amniotic shunting*

Vesico-amniotic shunting is the most common treatment for lower urinary tract obstruction. Shunting relieves pressure from urine buildup in the urinary tract (specifically the kidneys, ureters, and bladder) and reestablishes amniotic fluid volume to allow for lung growth. It has been shown to improve perinatal prognosis in small retrospective studies [11-13] and in a recent meta-analysis [14] (level V evidence), however, the effectiveness of this procedure in improving long-term prognosis for CAKUT has not been addressed in a large-scale study. A comprehensive study is needed to understand the long-term outcomes of vesicoamniotic shunting, but even with limited long-term data, it may be the best option for a fetus with a poor prognosis.

The concentration of essential electrolytes in fetal urine extracted from the bladder has been discussed as an indicator of the severity of renal complications. Crombleholme, et. al. established parameters for establishing prognoses based on bladder electrolyte concentrations. A good prognosis included levels of sodium <100 mEq/L, chloride <90 mEq/L, and osmolarity <210 mOsm/L. Survival rate of fetuses in this group were three times greater than those whose bladder electrolytes deviated from these values [15]. Glick, et. al. came to similar results in correlating bladder electrolyte balance with prognosis [16]. Recently use of urine electrolytes has diminished and bladder refilling after drainage has been used to determine the utility of a shunt [17].

### *Fetal cystoscopy*

Unlike vesico-amniotic shunting, cystoscopy aims to directly treat the pathophysiology of LUTO. It aims to treat urethral obstructions by passage of a fetoscope through the urethra and into the obstructed bladder. Laser technology and mechanical force are used to overcome obstruction from posterior urethral valves or urethral atresia [18]. A recent study reported a 2-year-survival rate of children with LUTO of greater than 50% after fetal cystoscopy to relieve obstruction. Although the procedure was not successful in the patients with urethral atresia, more than half of the children with prenatally-diagnosed PUV survived and almost  $\frac{3}{4}$  had restored renal function [19]. Cystoscopy is a difficult procedure with an associated learning curve, and its outcomes may improve as technique becomes more-widely practiced.

### *Serial amnioinfusions*

Serial amnioinfusions may alleviate pulmonary hypoplasia and other comorbidities in the setting of CoBRA or progressive oligohydramnios secondary to renal failure. Specifically for CoBRA the RAFT trial is attempting to assess the efficacy of serial amnioinfusions. There are also case reports of giving amnioinfusions through an implanted port [20]. There are no current IRB approved trials evaluating this therapy.

### *Open fetal surgery*

There is no current role for open fetal surgery in fetal GU anomalies.

### **Counseling**

Urinary and genital anomalies can be very sensitive topic to discuss with families because of the gravity of severe renal complications and the sexual and societal implications of a sexual deformity. For severe GU abnormalities the physicians should strive to paint a realistic picture of what survival will mean in the setting of neonatal renal failure.

### **Level of Evidence**

Grade C, Level 4 (Case series) unless otherwise stated

## References

- [1] Stefos T, Plachouras N, Sotiriadis A, Papadimitriou D, Almoussa N, Navrozoglou I, et al. Routine obstetrical ultrasound at 18-22 weeks: our experience on 7,236 fetuses. *The Journal of maternal-fetal medicine* 1999;8(2):64-9.
- [2] Underwood MA, Gilbert WM, Sherman MP. Amniotic fluid: not just fetal urine anymore. *Journal of perinatology : official journal of the California Perinatal Association* 2005;25(5):341-8.
- [3] Baskin LS MT, Wilkins-Haug L. Overview of fetal hydronephrosis. *UpToDate Login*; 2017.
- [4] Barbosa JA, Chow JS, Benson CB, Yorioka MA, Bull AS, Retik AB, et al. Postnatal longitudinal evaluation of children diagnosed with prenatal hydronephrosis: insights in natural history and referral pattern. *Prenatal diagnosis* 2012;32(13):1242-9.
- [5] Westland R, Schreuder MF, Ket JC, van Wijk JA. Unilateral renal agenesis: a systematic review on associated anomalies and renal injury. *Nephrology, dialysis, transplantation : official publication of the European Dialysis and Transplant Association - European Renal Association* 2013;28(7):1844-55.
- [6] Clinton CM, Chasen ST. Unilateral Fetal Renal Abnormalities: Are They Really Isolated? *Journal of ultrasound in medicine : official journal of the American Institute of Ultrasound in Medicine* 2016;35(3):561-4.
- [7] J C. *Obstetric imaging: Fetal diagnosis and care*. Elsevier Health Sciences; 2017.
- [8] P N. *Autosomal recessive polycystic kidney disease*. Update; 2004.
- [9] Hartung EA, Guay-Woodford LM. Autosomal recessive polycystic kidney disease: a hepatorenal fibrocystic disorder with pleiotropic effects. *Pediatrics* 2014;134(3):e833-45.
- [10] Clayton DB, Brock JW, 3rd. Prenatal ultrasonography: implications for pediatric urology. *Journal of pediatric urology* 2011;7(2):118-25.
- [11] Clark TJ, Martin WL, Divakaran TG, Whittle MJ, Kilby MD, Khan KS. Prenatal bladder drainage in the management of fetal lower urinary tract obstruction: a systematic review and meta-analysis. *Obstetrics and gynecology* 2003;102(2):367-82.
- [12] Ruano R, Sananes N, Wilson C, Au J, Koh CJ, Gargollo P, et al. Fetal lower urinary tract obstruction: proposal for standardized multidisciplinary prenatal management based on disease severity. *Ultrasound in obstetrics & gynecology : the official journal of the International Society of Ultrasound in Obstetrics and Gynecology* 2016;48(4):476-82.
- [13] Morris RK, Malin GL, Quinlan-Jones E, Middleton LJ, Diwakar L, Hemming K, et al. The Percutaneous shunting in Lower Urinary Tract Obstruction (PLUTO) study and randomised controlled trial: evaluation of the effectiveness, cost-effectiveness and acceptability of percutaneous vesicoamniotic shunting for lower urinary tract obstruction. *Health technology assessment (Winchester, England)* 2013;17(59):1-232.
- [14] Nassr AA, Shazly SAM, Abdelmagied AM, Araujo Junior E, Tonni G, Kilby MD, et al. Effectiveness of vesicoamniotic shunt in fetuses with congenital lower urinary tract obstruction: an updated systematic review and meta-analysis. *Ultrasound in obstetrics & gynecology : the official journal of the International Society of Ultrasound in Obstetrics and Gynecology* 2017;49(6):696-703.
- [15] Crombleholme TM, Harrison MR, Golbus MS, Longaker MT, Langer JC, Callen PW, et al. Fetal intervention in obstructive uropathy: prognostic indicators and efficacy of intervention. *American journal of obstetrics and gynecology* 1990;162(5):1239-44.
- [16] Glick PL, Harrison MR, Golbus MS, Adzick NS, Filly RA, Callen PW, et al. Management of the fetus with congenital hydronephrosis II: Prognostic criteria and selection for treatment. *Journal of pediatric surgery* 1985;20(4):376-87.
- [17] Hinman F BL. *Hinman's atlas of pediatric urologic surgery*. Elsevier Health Sciences; 2009.

- [18] Haeri S. Fetal Lower Urinary Tract Obstruction (LUTO): a practical review for providers. *Maternal health, neonatology and perinatology* 2015;1:26.
- [19] Sananes N, Cruz-Martinez R, Favre R, Ordorica-Flores R, Moog R, Zaloszy A, et al. Two-year outcomes after diagnostic and therapeutic fetal cystoscopy for lower urinary tract obstruction. *Prenatal diagnosis* 2016;36(4):297-303.
- [20] Polzin WJ, Lim FY, Habli M, Van Hook J, Minges M, Jaekle R, et al. Use of an Amnioport to Maintain Amniotic Fluid Volume in Fetuses with Oligohydramnios Secondary to Lower Urinary Tract Obstruction or Fetal Renal Anomalies. *Fetal diagnosis and therapy* 2017;41(1):51-7.